

Effectiveness of a Footprint Guide to Establish an Anatomic Femoral Tunnel in Anterior Cruciate Ligament Reconstruction: Computed Tomography Evaluation in a Cadaveric Model

Pablo Eduardo Gelber, M.D., Ph.D., Juan Erquicia, M.D., Ferrán Abat, M.D.,
Raúl Torres, M.D., Xavier Pelfort, M.D., Alfonso Rodriguez-Baeza, M.D.,
Xavier Alomar, M.D., and Juan Carlos Monllau, M.D., Ph.D.

Purpose: To compare drilling the femoral tunnel with an offset aimer and BullsEye guide (ConMed Linvatec, Largo, FL) to perform an anatomic single-bundle reconstruction of the anterior cruciate ligament (ACL) through the anteromedial portal. **Methods:** Seven matched pairs of cadaveric knees were studied. The intent was to drill the femoral tunnel anatomically in all cases. In group A the femoral tunnel was drilled arthroscopically with an offset aimer. In group B the femoral tunnel was drilled arthroscopically with the BullsEye guide. Two tunnels were drilled through the same entry point in each knee. One was done at 110° of knee flexion and the other at 130°. They were scanned by computed tomography and reconstructed 3-dimensionally. Volume-rendering software was used to document relations of the drilled tunnel to the bony anatomy and tunnel length. **Results:** In group B the femoral tunnel was placed at the center of the femoral insertion site. The center of the tunnel was 9.4 mm from the high cartilage margin and 8.6 mm from the low cartilage margin. In group A the tunnels were placed deeper (5.4 mm and 12.6 mm, respectively) ($P = .018$). There were no differences in tunnel length for either knee flexion degree. Three of the tunnels drilled at 110° in group A compromised the posterior tunnel wall and measured less than 25 mm in length. **Conclusions:** Accurate placement in the center of the femoral footprint of the ACL is better accomplished with the BullsEye guide rather than 5-mm offset aimers. Five-millimeter offset aimers might cause posterior tunnel blowout and present the risk of obtaining short tunnels when performing oblique femoral tunnel placement through the anteromedial portal at 110° of knee flexion. **Clinical Relevance:** The BullsEye guide might be better than standard offset aimers in the performance of anatomic single-bundle ACL reconstruction.

From the Department of Orthopaedic Surgery, Hospital de Sant Pau (P.E.G., F.A., J.C.M.), Department of Morphological Sciences (Anatomy and Embryology Unit), Faculty of Medicine (P.E.G., A.R.-B.), Institut Universitari Dexeus (P.E.G., J.E., X.P., J.C.M.), and Department of Orthopaedic Surgery, Parc de Salut Mar (R.T., X.P.), Universitat Autònoma de Barcelona; and Department of Radiology, Creu Blanca (X.A.), Barcelona, Spain.

The authors report no conflict of interest.

Received June 19, 2010; accepted February 4, 2011.

Address correspondence to Pablo Eduardo Gelber, M.D., Ph.D., Department of Orthopaedic Surgery, Hospital de Sant Pau, Universitat Autònoma de Barcelona. C/ Sant Antoni Maria Claret, 167-08025 Barcelona, Spain. E-mail: pablogelber@gmail.com

*© 2011 by the Arthroscopy Association of North America
0749-8063/10364/\$36.00*

doi:10.1016/j.arthro.2011.02.004

Fixation of the anterior cruciate ligament (ACL) high in the notch has been the leading technique over the last 20 years.¹ However, this nonanatomic femoral tunnel placement cannot satisfactorily achieve the required rotatory knee stability.

There are 2 widely used techniques for creating the femoral tunnel. One is performed by drilling through the tibial tunnel (transtibial technique), and the other is performed by drilling through the anteromedial (AM) portal (AM portal technique). Placing the graft at the center of the anatomic insertion site with a transtibial technique is not always easily done.²⁻⁴ Some surgeons have advocated independent drilling of the femoral tunnel. Thus drilling the femoral tunnel through a low accessory AM portal has become another option for placing the graft anatomically.^{5,6}

There are also different methods to aid in drilling the femoral tunnel. Whereas some surgeons drill the tunnel over a guidewire inserted directly at the desired femoral site,⁷ others insert the guidewire with the help of femoral drill guides. One of the drill guides, the standard femoral offset aimer, was originally developed to assist in establishing sufficient posterior placement of the femoral tunnel when drilling with a transtibial technique while minimizing the risk of posterior blowout. Although new specific AM portal offset guides have been developed by industry in recent years to better assist anatomic reconstruction, many authors who have changed to an AM portal drilling technique are still using standard offset femoral aimers.⁸⁻¹² Guides other than those based on the distance to the posterior cortex have also been developed. One of them, the BullsEye Femoral Footprint guide (ConMed Linvatec, Largo, FL), has a window at its oval end for easy visualization of the desired guide pin placement (Fig 1). This guide also allows the surgeon to pre-visualize where the femoral tunnel with its final size will be after drilling. The precision and potential advantages of this new guide have never been objectively evaluated.

With regard to the evaluation of tunnel placement, Purnell et al.¹³ have recently described the ACL femoral insertion site through the use of high-resolution computed tomography (CT) with 3-dimensional (3D) reconstructions and volume-rendering software. Recently, evaluating the placement of the tunnels in ACL reconstruction with this technique has become more popular, and proper anatomic tunnel placement on 3D




FIGURE 1. BullsEye Femoral Footprint guide. Its open tip allows for easy visualization of the femoral footprint. Inset, Complete BullsEye guide.

CT images has been described by Basdekis et al.¹⁴ Forsythe et al.¹⁵ have also very recently defined the position of anatomic femoral tunnels on 3D CT reconstruction images by adapting the quadrant method described by Bernard et al.¹⁶ on lateral standard radiographs.

The aim of this work was to compare a standard offset femoral aimer versus the BullsEye guide in the performance of an anatomic single-bundle reconstruction through the AM portal with CT images. Another goal was to define the length of the femoral tunnels placed at 2 different degrees of knee flexion. The last purpose was to assess the safety of both aimers in guiding the femoral tunnel drilling at 2 different degrees of knee flexion.

The first hypothesis of the study was that the BullsEye guide, in comparison to the offset femoral aimer, would allow for a more anatomic placement of the femoral tunnel. The second hypothesis was that higher knee flexion would allow for longer femoral tunnels.

METHODS

Seven matched pairs of whole-lower extremity fresh knees from cadaveric volunteer donors were studied. There were 4 male donors and 3 female donors, whose ages ranged from 54 to 85 years (mean, 76 years). The specimens had been stored at -18°C . They were then thawed at room temperature for 24 to 36 hours before testing. None of the knees showed macroscopic signs of previous surgery or degenerative changes. Preoperative mobility, measured with a goniometer, showed minimum flexion of 135° . Full extension was still possible. The specimens were mounted on a knee holder (Extremity Holder; Sawbones, Malmö, Sweden).

By use of a long metal ruler, the longitudinal axis of the thigh—defined as the line passing through the greater trochanter and the lateral epicondyle—was marked with a skin pen. The longitudinal axis of the leg passing through the center of the fibular head and the lateral malleolus was also marked. A manual goniometer was used to measure the angle between the 2 lines so that femorotibial flexion could be calculated.

One of the knees of a pair was assigned to receive a femoral tunnel drilled with a standard 5-mm offset aimer (group A), whereas the other was assigned to receive a femoral tunnel drilled with the help of the newly designed BullsEye guide. The matched pairs were used to minimize anatomic differences between specimens.

Arthroscopic Procedure

All surgical procedures were carried out by the same surgeon under the supervision and with the agreement of 2 of the other authors. Only when the 3 experienced surgeons agreed on tunnel placement was the tunnel drilled. The knees hung freely at 90° of flexion except when the femoral tunnels were being drilled. A high anterolateral portal was established as the initial viewing portal. A parapatellar AM portal was also then created as a viewing portal so that the medial wall of the lateral condyle could be better seen. Finally, an accessory AM portal was established as the working portal. This portal was set as distally as possible with the help of a spinal needle under direct visualization to avoid injuring the anterior horn of the medial meniscus. In addition, the portal was placed as medial as possible without injuring the medial femoral condyle.

After excision of the ACL, the lateral wall of the intercondylar notch was cleared with the help of a shaver, leaving 1 to 2 mm of the ACL femoral stump.

In group A the femoral tunnel placement was selected with the help of a 5-mm offset aimer (Fig 2A). The clock-face position was carefully placed at the 10-o'clock (right knees) and 2-o'clock (left knees) positions with reference to the inside of the notch. This is known to be the intermediate point between the AM and posterolateral (PL) bundles in the high/low position.¹⁷ In group B the femoral tunnel placement was selected with the help of the BullsEye femoral guide (Fig 2B). Its open design allows for easy viewing of the ACL femoral footprint. The center of the tunnel was drilled at an intermediate point between the AM and PL femoral footprints or in the center of the lateral bifurcate ridge when this had been clearly identified. In each of the knees of both groups, the procedure was as follows: (1) a 2.5-mm K-wire was drilled at 110° of knee flexion and subsequently over-reamed with a 5-mm cannulated reamer; (2) the K-wire was drilled at the same entry point but at 130° of knee flexion, and then it was also over-reamed to 5 mm; and (3) the first 10 to 15 mm of the entry point of the femoral tunnel was over-reamed to 8 mm. This was done to obtain better mapping of the anatomic single-bundle reconstruction on 3D CT imaging analysis because this 8-mm tunnel diameter is commonly seen in the clinical setting (Fig 3). This was also performed at 130° of knee flexion.

CT Scanning

All knees were placed in full extension and imaged on multiple planes on a Toshiba Aquilon CT Scan

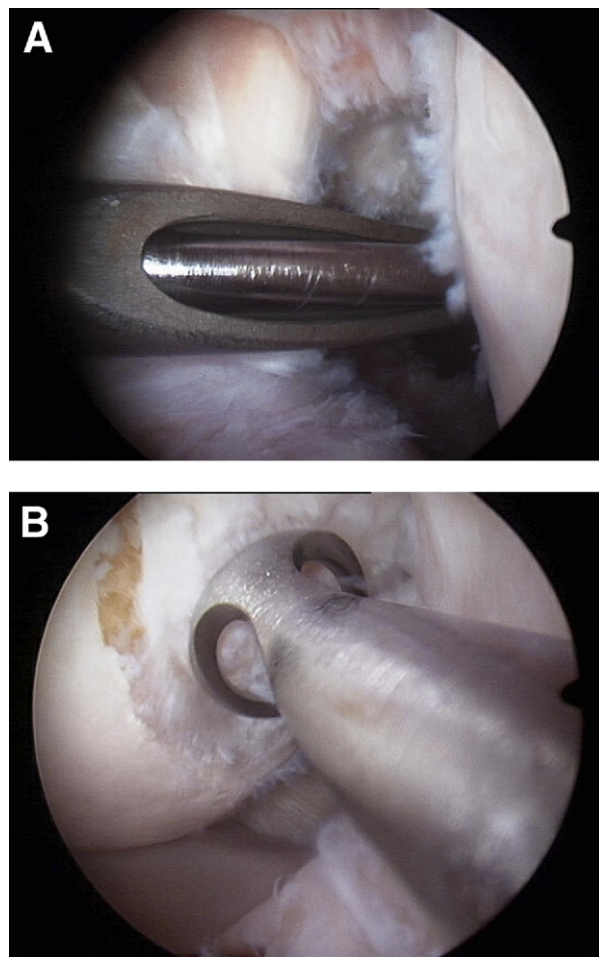


FIGURE 2. (A) Arthroscopic view of right knee from anterolateral portal. In group A the femoral tunnel was drilled with assistance from an offset aimer. (B) Arthroscopic view of left knee from AM portal. In group B the BullsEye guide aided the proper placement of the femoral tunnel.

TSX-101A (Toshiba Medical Systems, Tochigi-Ken, Japan) to generate high-resolution 3D images of the placed tunnels. EFilm Workstation 2.1.2 integrated view and processing software (Merge Healthcare, Hartland, WI) allowed for the removal of the medial femoral condyle to visualize the lateral wall of the intercondylar notch. Images that were coplanar with the tunnels were also analyzed. One radiologist, an expert in musculoskeletal imaging, performed all measurements twice and then averaged them. The following parameters, all of them expressed in millimeters, were measured in all matched-pair knees:

- The shortest distance from the center of the 8-mm tunnel to the posterior margin of the articular cartilage (deep in the notch) was calculated. This was

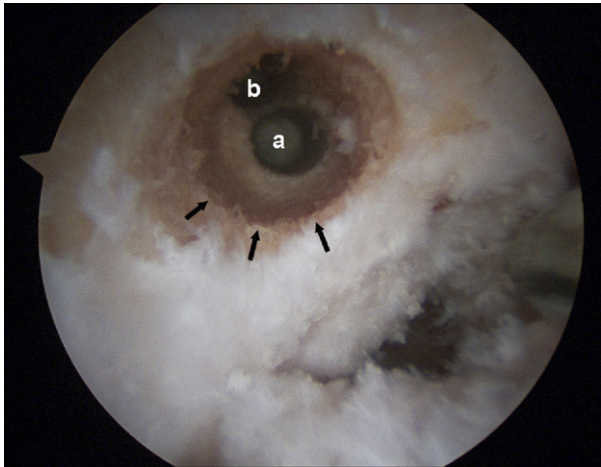


FIGURE 3. Arthroscopic view of right knee. Two divergent 5-mm tunnels are seen. The lower tunnel was placed at 110° of knee flexion (a), whereas the other tunnel was drilled at 130° (b). The first 15 mm of the entry point was over-drilled to 8 mm (arrows).

called the distance to the proximal cartilage margin (DPCM). This measurement was based on the studies performed by Colombet et al.² and Basdekis et al.¹⁴

- The shortest distance from the center of the 8-mm tunnel to the anteroinferior margin of the articular cartilage (low in the notch) was calculated. This was called the distance to the distal cartilage margin (DDCM) (Fig 4). This measurement was based on the same study as the DPCM.^{2,14}
- The position of the tunnel was calculated with the quadrant method described by Forsythe et al.¹⁵ On a true medial view of the femur established at 90° of knee flexion, a 4×4 grid was applied to the 3D CT images. Following the recommendations of Forsythe et al., the most anterior edge of the femoral notch roof was chosen as the reference for the grid alignment.

The previously mentioned measurements were calculated on the reconstructed 3D images. The following measurements were calculated on selected images that were coplanar with the tunnel to allow for a direct measurement from the intra-articular to the extra-articular apertures:

- The length of the 2 tunnels in each knee was measured, i.e., the tunnel length drilled at 110° of knee flexion in group A or B and the tunnel length drilled at 130° of knee flexion in group A or B. Because lateral femoral condyles have a rounded shape and the tunnel is not drilled orthogonally, the measured length may vary depending on whether the anterior

or posterior border of the tunnel is used as the reference. Therefore the tunnel length was measured in the center of the tunnel. Tunnels shorter than 25 mm, which is the minimum length recommended,^{9,10,18} were recorded.

- The divergence angle (TDA) between the tunnel drilled at 110° of knee flexion and the tunnel drilled at 130° of knee flexion was calculated.
- The shortest distance between both tunnels in the exit point at the lateral femoral cortex was calculated from coplanar images.
- Posterior wall compromise was defined by any breach in the posterior cortical wall of the tunnel that was evident on any CT image.

Statistical Analysis

Categorical variables are presented as percentages and frequencies. For each continuous variable, mean and standard deviation as well as median and quartiles were calculated. Because of the small sample number and the difficulty of determining whether the variables were or were not adjusted to a normal distribution, the paired nonparametric Wilcoxon test was used to compare the measurements in both groups. These continuous variables are presented as medians. Statistical analysis was performed with SPSS software, version 15 (SPSS, Chicago, IL). Statistical significance was set at the .05 level.

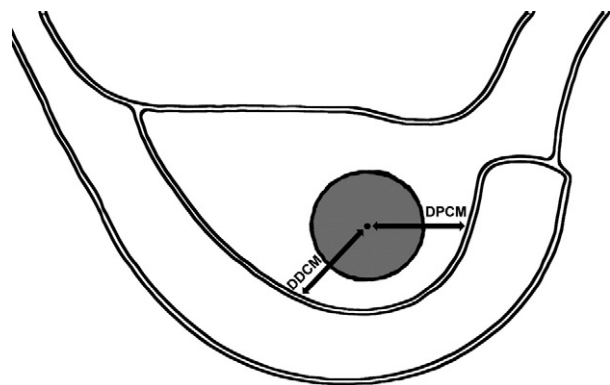


FIGURE 4. Morphometric parameters of tunnel positioning measured on lateral wall of intercondylar notch. The DPCM's arrow corresponds to the shortest distance from the center of the tunnel to the posterior margin (deep in the notch) of the articular cartilage. The DDCM's arrow corresponds to the shortest distance from the center of the tunnel to the anteroinferior margin (low in the notch) of the articular cartilage.

RESULTS

In group B the femoral tunnel was at about the midpoint of the medial wall of the lateral condyle in the sagittal plane (deep/shallow position) (Fig 5). On the other hand, the femoral tunnels drilled in the specimens corresponding to group A were placed deeper and right near the posterior cortical wall (Fig 6). In group B the median DPCM was 9.4 mm and the median DDCM was 8.6 mm. On the other hand, the median DPCM was 5.4 mm and the median DDCM was 12.6 mm in group A ($P = .018$ for both measurements). These results are summarized in Table 1. Similarly, when the deep/shallow position was analyzed with the quadrant method on 3D scan images,¹⁵ the tunnel was deeper in group A (19.7%) than in group B (26.9%) ($P = .018$).

Analysis of the coronal plane showed that tunnels placed in group A had a median high/low position of 30.3%. In group B the tunnels were placed lower, at a median high/low position of 40.8% ($P = .018$).

The tunnel length showed no differences when we compared the tunnels of both groups drilled at either

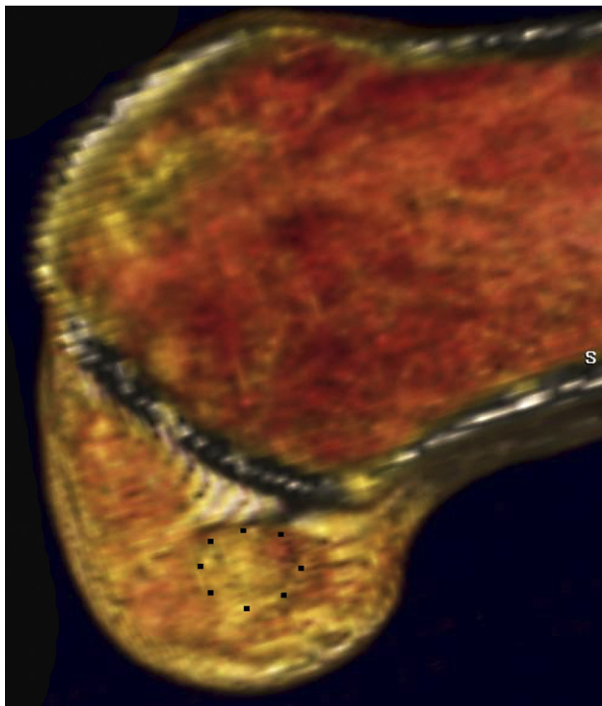


FIGURE 5. Three-dimensional CT scan reconstruction. In the BullsEye group (group B), the drilled single tunnel was generally in the center of the femoral footprint, as shown in this sample. A dotted circle was added to better aid in distinguishing the drilled tunnel.

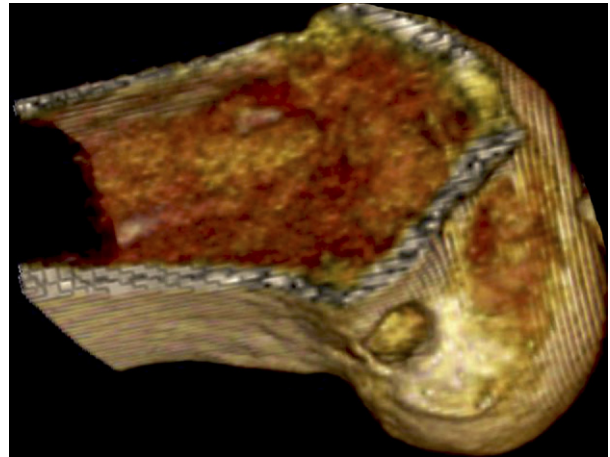


FIGURE 6. Three-dimensional CT scan image. The location of the tunnel aperture center in the 5-mm standard offset aimer group (group A) was generally established deep in the notch, as shown in this specimen.

110° ($P = .18$) or 130° ($P = .24$) of knee flexion. There was also no statistical difference when comparing them within the same groups (group A, $P = .091$; group B, $P = .15$). However, 3 of the tunnels drilled at 110° of knee flexion with the offset aimer (group A) were shorter than 25 mm (17, 20, and 23.1 mm) (Fig 7). Table 2 provides a summary of the different tunnel length measurements.

The tunnels drilled at 110° and 130° of knee flexion diverge from each other in the same proportion to the same degree. The TDA was 15.6° in group A and 17.9° in group B ($P = .18$). Similarly, the distance from the lateral exit point of the tunnels placed at 110° of knee flexion to the tunnels placed at 130° of knee flexion was equivalent when comparing 1 group with the other. The median TDA was 15.6 mm in group A and 17.9 mm in group B ($P = .73$).

TABLE 1. Distances From Center of Drilled Femoral Tunnels to Cartilage Margin in Lateral Wall of Intercondylar Notch With Standard 5-mm Offset Aimer (Group A) and With BullsEye Guide (Group B)

	Minimum (mm)	Maximum (mm)	Median (mm)
DPCM			
Group A	4.7	6.7	5.4
Group B	8.5	14	9.4
DDCM			
Group A	10.1	16.1	12.6
Group B	7.2	10.9	8.6

Abbreviations: DPCM, distance to proximal (deep) cartilage margin; DDCM, distance to distal (low) cartilage margin.

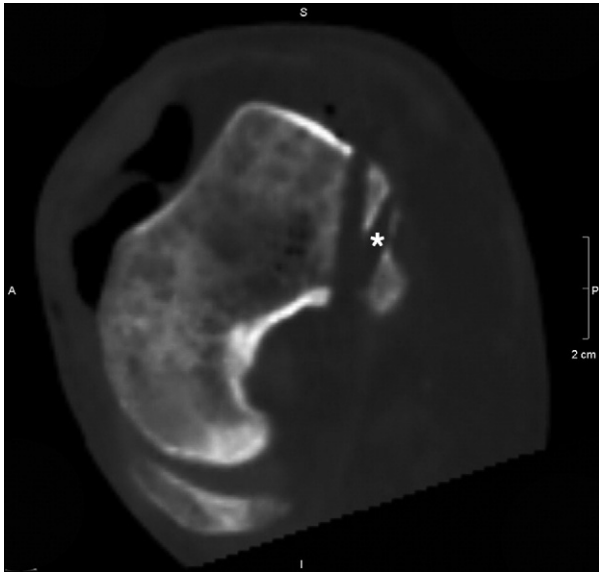


FIGURE 7. CT scan image, coplanar with both tunnels. The posterior tunnel (asterisk), which was drilled with the help of the offset aimer at 110° of knee flexion, measured only 23 mm in length.

Finally, the tunnels drilled at 110° of knee flexion caused partial compromise of the posterior tunnel wall in 3 of 7 knees corresponding to group A (Fig 8). These partial breakages caused the aforementioned short tunnels.

DISCUSSION

The principal finding of this study was that placement of a single femoral tunnel at the anatomic insertion is better accomplished with the BullsEye guide rather than with offset aimers. The aforementioned finding confirms our first hypothesis.

TABLE 2. Tunnel Lengths Corresponding to Drilled Femoral Tunnel With Standard 5-mm Offset Aimer (Group A) and With BullsEye Guide (Group B) at 110° and 130° of Knee Flexion

	Minimum (mm)	Maximum (mm)	Median (mm)
TL 110°			
Group A	17	42	30
Group B	27	40	34.7
TL 130°			
Group A	30	37.2	35.5
Group B	26	42	32

Abbreviations: TL 110° , tunnel length drilled at 110° of knee flexion; TL 130° , tunnel length drilled at 130° of knee flexion.

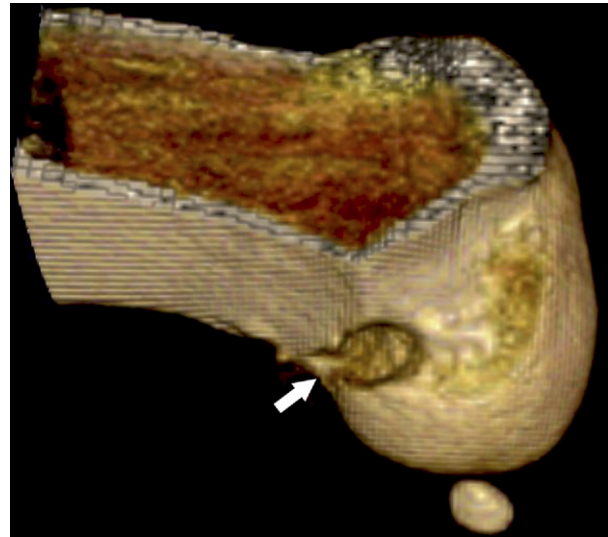


FIGURE 8. Three-dimensional CT scan image, showing posterior tunnel wall compromise (arrow). The breach of the femoral tunnel was produced in this specimen and in 2 other specimens where the selection of the drilling site was done with the offset aimer at 110° of knee flexion.

The degree of knee flexion during drilling of the femoral tunnel is controversial. Currently, knee hyperflexion is recommended to provide increased tunnel length.^{18,19} However, Bedi et al.¹⁰ showed a paradoxical reduction in tunnel length, as well as an increased risk of posterior tunnel blowout. They suggested that this could be because of their use of a femoral offset guide when drilling through the AM portal. In contrast to our second hypothesis, no differences were observed in tunnel length when we compared 110° and 130° of knee flexion with either the standard offset aimer or the BullsEye guide in this study. However, we observed longer tunnels when using the latter guide. This might be because of posterior wall referencing with the offset aimer when drilling at a high degree of knee flexion through the AM portal. Paradoxically, this may increase the posterior trajectory of the guidewire and thereby increase the risk of short tunnels and blowout.¹⁰ Three of the tunnels drilled at 110° of knee flexion with the offset aimer partially compromised the posterior walls of the tunnels. This suggests that the BullsEye guide might be safer than the 5-mm standard offset guide used at 110° of knee flexion. Furthermore, those 3 tunnels were all shorter than 25 mm, which is less than the minimum recommended tunnel length.^{9,10,18} In the study performed by Bedi et al., this was found in an even higher proportion. They observed posterior wall compromise in

75% of the tunnels placed at 120° of knee flexion, all of which had a mean length of 21.3 mm.

Persistent rotatory instability has been shown to result in an inferior subjective functional outcome and earlier articular degeneration.²⁰ Therefore looking for a technique that could reduce this stability deficit should be mandatory. Several studies have recently shown, biomechanically, that placing the femoral tunnel through a single-bundle technique at the center of the anatomic origin of the ACL more closely restores rotational stability to the knee than does the standard tunnel reconstruction high and deep in the notch, near the so-called over-the-top position.²¹⁻²³ In an attempt to approach the anatomic femoral insertion of the ACL, some surgeons have suggested lowering the femoral offset aimers⁸⁻¹² from the high- and deep-in-the-notch position that is commonly used with the transtibial technique. This is better accomplished by drilling the tunnel through the AM portal.³⁻⁵ However, to reach the anatomic center of the ACL femoral footprint, not only a lower but also a shallower tunnel is necessary.² In this study high-resolution CT with 3D reconstruction and volume-rendering software were used to evaluate the femoral tunnel placement. This technique allows for multiplanar visualization of the acquired image and the removal of tissue as needed to allow for measurements of the desired structures and their relations to each other. Purnell et al.¹³ have recently described the ACL femoral insertion site using the same technique. They showed that, on the lateral femoral condyle, the posterior fibers of the ACL ended 3.5 mm from the proximal articular cartilage margin whereas the anteroinferior fibers did so at 3 mm to the distal cartilage margin. In the study performed by Basdekis et al.,¹⁴ similar results were observed. The most posterior fibers of the ACL ended 1.6 mm from the articular margin, and the most distal fibers ended 2.2 mm from the articular margin. They also showed that for an ACL double-bundle reconstruction to be considered anatomic, it must show similar results. In this case the posterior border of the AM tunnel has to be used for referencing with the proximal cartilage margin and the anteroinferior border of the PL tunnel for the distal cartilage margin. This was also in agreement with the study performed by Girgis et al.²⁴ in 44 dissected cadaveric knees. In their study the mean distance from the posterior fibers of the ACL to the articular surface of the femoral condyle was 4 mm. In our study the single tunnel placed with the BullsEye guide showed a comparable position to all the aforementioned studies. They all showed similar distances to the prox-

imal as well to the distal cartilage margin. Conversely, when the tunnel was placed with the help of the femoral offset guide, we obtained 1 tunnel that was deeper than the anatomic footprint center. Forsythe et al.¹⁵ have recently described the position of the AM and PL bundles on 3D CT reconstruction images by adapting the radiographic quadrant method described earlier.¹⁶ They have shown that it has high levels of intraobserver and interobserver reliability. They observed mean deep/shallow positions of the AM and PL bundles of 21.7% and 35.1%, respectively, and mean high/low positions of the AM and PL bundles of 33.2% and 55.3%, respectively. In our study the single-tunnel placement with the offset aimer was performed at a median of 19.7% and 30.3% for the deep/shallow and high/low positions, respectively. This was very similar to the AM bundle position described in the work of Forsythe et al. On the other hand, the single-tunnel placement with the BullsEye guide was performed at a median of 26.9% and 40.8% for the deep/shallow and high/low positions, respectively. This corresponded to an intermediate position between both the AM and PL bundles. In this sense, the experimental work performed by Kato et al.,²⁵ which has shown that placing the femoral tunnel in the middle of the femoral footprint reproduces the in situ force of the normal ACL better than any other single-bundle ACL reconstruction, is interesting. For that reason and according to the specific placement results observed in our study, performing femoral tunnel placement with the BullsEye guide rather than with offset aimers might better restore the normal kinematics of the knee.

There are some limitations to this study. Some of the non-statistically significant differences observed might be because of the small sample size, which is a common limitation in cadaveric studies. We did not perform an a priori sample analysis. This may be because no differences were observed in tunnel length when comparing the 2 techniques evaluated and the 2 different degrees of knee flexion. However, comparing knees from the same cadaver theoretically minimizes size differences. Second, only the 8-mm BullsEye guide was compared with 5-mm offset aimers. Higher offset aimers could logically move the drilled tunnel closer to the anatomic site. However, we will still be using the same fixed distance from the posterior wall instead of looking for the specific anatomic center in each knee. Finally, neither interobserver nor intraobserver reliability was calculated for the measurements.

CONCLUSIONS

Accurate placement at the center of the femoral footprint of the ACL is better accomplished with the BullsEye guide rather than with standard 5-mm offset aimers. Five-millimeter offset aimers might cause posterior tunnel blowout and present the risk of obtaining short tunnels when performing oblique femoral tunnel placement through the AM portal at 110° of knee flexion.

Acknowledgment: The authors appreciate Esther Moya and Ignacio Cardona for their help with the arthroscopic procedures and Manel Querol for his special contribution of preparing the specimens. They are also grateful to Sergi Mojal for assisting in the statistical analysis. Finally, they thank Eric Goode for his help in correcting the manuscript.

REFERENCES

1. Bylski-Austrow DI, Grood E, Hefzy M, Holden JP, Butler DL. Anterior cruciate ligament replacements: A mechanical study of femoral attachment location, flexion angle at tensioning and initial tension. *J Orthop Res* 1990;8:522-532.
2. Colombet P, Robinson J, Christel P, et al. Morphology of anterior cruciate ligament attachments for anatomic reconstruction: A cadaveric dissection and radiographic study. *Arthroscopy* 2006;22:984-992.
3. Albuquerque RF, Amatuzzi MM, Pacheco AP, Angelini FJ, Campos O Jr. Positioning of the femoral tunnel for arthroscopic reconstruction of the anterior cruciate ligament: Comparative study of 2 techniques. *Clin Sao Paulo Brazil* 2007;62:613-618.
4. Arnold MP, Kooloos J, van Kampen A. Single-incision technique misses the anatomical femoral anterior cruciate ligament insertion: A cadaveric study. *Knee Surg Sports Traumatol Arthrosc* 2001;9:194-199.
5. Gavriilidis I, Motsis EK, Pakos EE, Georgoulis AD, Mitsionis G, Xenakis TA. Trans tibial versus anteromedial portal of the femoral tunnel in ACL reconstruction: A cadaveric study. *Knee* 2008;15:364-367.
6. Harner C, Honkamp N, Ranawat AS. Anteromedial portal technique for creating the anterior cruciate ligament femoral tunnel. *Arthroscopy* 2008;24:113-115.
7. Cha PS, Brucker PU, West RV, et al. Arthroscopic double-bundle anterior cruciate ligament reconstruction: An anatomic approach. *Arthroscopy* 2005;21:1275-1277.
8. Gelber PE, Reina F, Torres R, Pelfort X, Tey M, Monllau JC. Anatomic single-bundle anterior cruciate ligament reconstruction from the anteromedial portal: Evaluation of transverse femoral fixation in a cadaveric model. *Arthroscopy* 2010;26:651-657.
9. Gelber PE, Torres R, Reina F, Monllau JC. Effect of femoral tunnel length on the safety of anterior cruciate ligament graft fixation using cross-pin technique: A cadaveric study. *Am J Sports Med* 2010;38:1877-1884.
10. Bedi A, Raphael B, Maderazo A, et al. Drilling for anterior cruciate ligament reconstruction: A cadaveric study of femoral tunnel length and obliquity. *Arthroscopy* 2010;26:342-350.
11. Sastre S, Popescu D, Núñez M, Pomes J, Tomas X, Peidro L. Double-bundle versus single-bundle ACL reconstruction using the horizontal femoral position: A prospective, randomized study. *Knee Surg Sports Traumatol Arthrosc* 2010;18:32-36.
12. Yasuda K, Kondo E, Ichiyama H, et al. Anatomic reconstruction of the anteromedial and posterolateral bundles of the anterior cruciate ligament using hamstring tendon grafts. *Arthroscopy* 2004;20:1015-1025.
13. Purnell ML, Larson AE, Clancy W. Anterior cruciate ligament insertions on the tibia and femur and their relationships to critical bony landmarks using high-resolution volume-rendering computed tomography. *Am J Sports Med* 2008;36:2083-2090.
14. Basdekis G, Christel P, Anne F. Validation of the position of the femoral tunnels in anatomic double-bundle ACL reconstruction with 3-D CT scan. *Knee Surg Sports Traumatol Arthrosc* 2009;17:1089-1094.
15. Forsythe B, Kopf S, Wong AK, et al. The location of femoral and tibial tunnels in anatomic anterior cruciate ligament reconstruction analyzed by three-dimensional computed tomography models. *J Bone Joint Surg Am* 2010;92:1418-1426.
16. Bernard M, Hertel P, Hornung H, Cierpinski T. Femoral insertion of the ACL. Radiographic quadrant method. *Am J Knee Surg* 1997;10:14-21; discussion, 21-22.
17. Rue JP, Ghodadra N, Bach BR Jr. Femoral tunnel placement in single-bundle anterior cruciate ligament reconstruction: A cadaveric study relating transtibial lateralized femoral tunnel position to the anteromedial and posterolateral bundle femoral origins of the anterior cruciate ligament. *Am J Sports Med* 2008;36:73-79.
18. Basdekis G, Abisafi C, Christel P. Influence of knee flexion angle on femoral tunnel characteristics when drilled through the anteromedial portal during anterior cruciate ligament reconstruction. *Arthroscopy* 2008;4:459-464.
19. Pujol N, Thierry D, Bauer T, Hardy P. Transverse femoral fixation in anterior cruciate ligament (ACL) reconstruction with hamstrings grafts: An anatomic study about the relationships between the transcondylar device and the posterolateral structures of the knee. *Knee Surg Sports Traumatol Arthrosc* 2006;14:724-729.
20. Jonsson H, Riklund-Ahlström K, Lind J. Positive pivot shift after ACL reconstruction predicts later osteoarthritis. 63 patients followed 5-9 years after surgery. *Acta Orthop Scand* 2004;75:594-599.
21. Loh JC, Fukuda Y, Tsuda E, Steadman RJ, Fu FH, Woo SL-Y. Knee stability and graft function following anterior cruciate ligament reconstruction: Comparison between 11 o'clock and 10 o'clock femoral tunnel placement. *Arthroscopy* 2003;3:297-304.
22. Musahl V, Plakseychuk A, VanScyoc A, et al. Varying femoral tunnels between the anatomical footprint and isometric positions. Effect on kinematics of the anterior cruciate ligament-reconstructed knee. *Am J Sports Med* 2005;5:712-718.
23. Scopp JM, Jasper LE, Belkoff SM, Moorman CT III. The effect of oblique femoral tunnel placement on rotational constraint of the knee reconstructed using patellar tendon autografts. *Arthroscopy* 2004;3:294-299.
24. Girgis FG, Marshall JL, Monajem ARS. The cruciate ligaments of the knee joint: Anatomical, functional, and experimental analysis. *Clin Orthop Relat Res* 1975:216-231.
25. Kato Y, Ingham JM, Fu FH. Effect of tunnel position for anatomic single-bundle ACL reconstruction on knee biomechanics in a porcine model. *Knee Surg Sports Traumatol Arthrosc* 2010;18:2-10.