



Posterolateral corner of the knee: an expert consensus statement on diagnosis, classification, treatment, and rehabilitation

Jorge Chahla¹ · Iain R. Murray² · James Robinson^{8,9} · Koen Lagae¹⁰ · Fabrizio Margheritini¹¹ · Brett Fritsch¹² · Manuel Leyes¹³ · Björn Barenius¹⁴ · Nicolas Pujol^{15,16} · Lars Engebretsen¹⁷ · Martin Lind¹⁸ · Moises Cohen¹⁹ · Rodrigo Maestu²⁰ · Alan Getgood²¹ · Gonzalo Ferrer²⁸ · Silvio Villascusa²⁶ · Soshi Uchida³¹ · Bruce A. Levy²³ · Richard Von Bormann²⁴ · Charles Brown²⁵ · Jacques Menetrey²⁹ · Michael Hantes³⁰ · Timothy Lording³² · Kristian Samuelsson^{5,33} · Karl Heinz Frosch^{6,7} · Juan Carlos Monllau²⁷ · David Parker¹² · Robert F. LaPrade²² · Pablo E. Gelber^{3,4}

Received: 20 August 2018 / Accepted: 23 October 2018
© European Society of Sports Traumatology, Knee Surgery, Arthroscopy (ESSKA) 2018

Abstract

Purpose To develop a statement on the diagnosis, classification, treatment, and rehabilitation concepts of posterolateral corner (PLC) injuries of the knee using a modified Delphi technique.

Methods A working group of three individuals generated a list of statements relating to the diagnosis, classification, treatment, and rehabilitation of PLC injuries to form the basis of an initial survey for rating by an international group of experts. The PLC expert group (composed of 27 experts throughout the world) was surveyed on three occasions to establish consensus on the inclusion/exclusion of each item. In addition to rating agreement, experts were invited to propose further items for inclusion or to suggest modifications of existing items at each round. Pre-defined criteria were used to refine item lists after each survey. Statements reaching consensus in round three were included within the final consensus document.

Results Twenty-seven experts (100% response rate) completed three rounds of surveys. After three rounds, 29 items achieved consensus with over 75% agreement and less than 5% disagreement. Consensus was reached in 92% of the statements relating to diagnosis of PLC injuries, 100% relating to classification, 70% relating to treatment and in 88% of items relating to rehabilitation statements, with an overall consensus of 81%.

Conclusions This study has established a consensus statement relating to the diagnosis, classification, treatment, and rehabilitation of PLC injuries. Further research is needed to develop updated classification systems, and better understand the role of non-invasive and minimally invasive approaches along with standardized rehabilitation protocols.

Level of evidence Consensus of expert opinion, Level V.

Keywords Posterolateral corner · Knee · Expert · Consensus · Lateral collateral ligament · Popliteus · Reconstruction

Introduction

The posterolateral corner (PLC) was once considered the “dark side” of the knee, and it was not until recent times that consistent anatomic and biomechanical descriptions aided in improved outcomes [3, 8, 29]. Several factors may have contributed to previous inconsistent results including poorly defined diagnostic techniques, [11, 23, 30] non-operative treatment of high-grade or combined injuries [10, 19] and

reconstructive procedures that failed to restore the native anatomy or biomechanics [17]. Understanding of PLC injuries including mechanisms of injury, the natural history of PLC pathology, and advances in the treatment (biomechanically validated anatomic reconstructions techniques [3]) and rehabilitation protocols with early range of motion to avoid arthrofibrosis [28] have increased markedly over the last two decades.

Despite considerable attention in the clinical orthopaedic literature (nearly 400 articles published in the last decade) a standardized algorithm for the diagnosis and treatment of these injuries is lacking, and controversies relating to these injuries remain. For the above-mentioned reasons,

✉ Jorge Chahla
jachahla@msn.com

Extended author information available on the last page of the article

the purpose of this article was to develop an international consensus statement on the diagnosis, classification, treatment, and rehabilitation concepts of posterolateral corner (PLC) injuries of the knee. The overall goal of this study was to provide guidance on widely accepted and controversial issues regarding the management of PLC injuries as well as future directions for further research to address important gaps in the literature.

Materials and methods

A working group of three individuals (initials blinded for review) was made responsible for facilitating the development of consensus using modified Delphi techniques under the leadership of the chair of the Knee Collateral Ligament working group (initials blinded for review) and the consensus project leader (initials blinded for review).

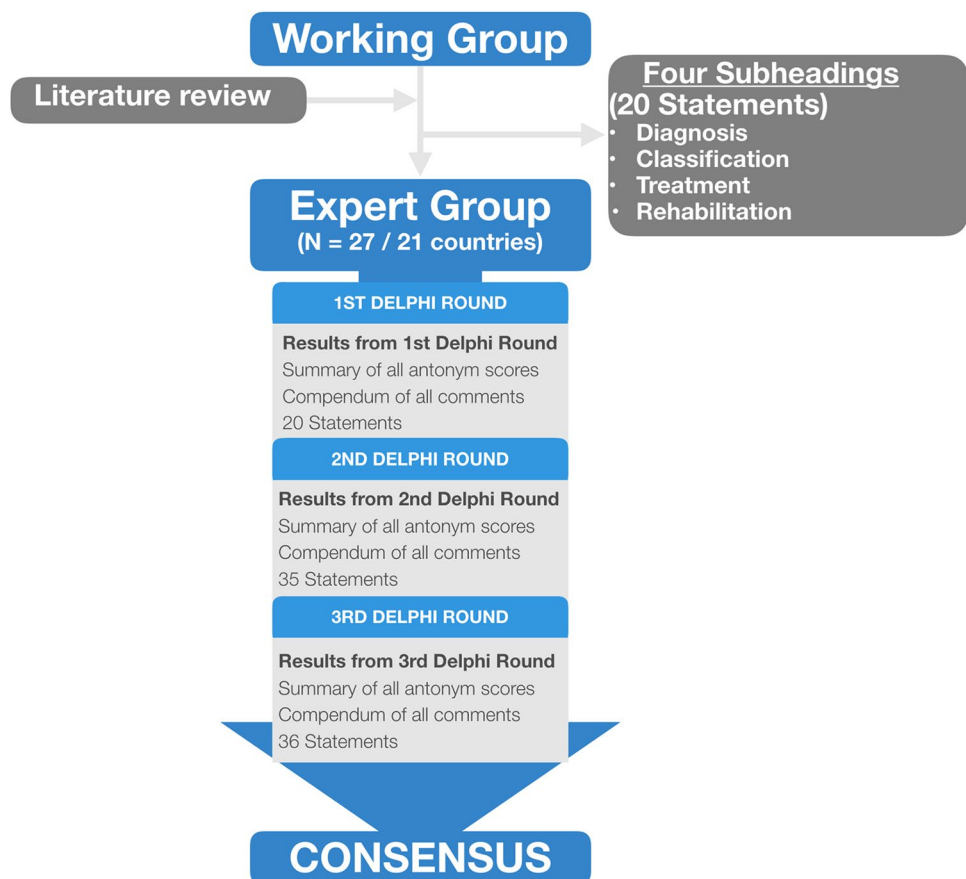
Given the complexity and heterogeneity in the management of posterolateral corner injuries reported in the literature, [2, 3, 8, 26, 30] it was decided to develop an expert consensus statement to also highlight the areas of further research. Figure 1 outlines the process used to develop the expert consensus. A comprehensive list of statements was generated under four categories: diagnosis, classification,

treatment, and rehabilitation to aid in a broad set of concepts to effectively manage PLC injuries. The PLC expert group was surveyed on three occasions to establish consensus on the inclusion/exclusion of each item. In addition to rating agreement through a Likert Scale, experts were encouraged to propose further items or modifications. Pre-defined criteria were used to refine item lists after each survey. Finally, the working group compiled the final information to represent the additive opinion of the expert panel.

Identification of items for inclusion in first-round survey

Potential information items for inclusion within first-round survey were prepared by the working group on the basis of two recently published systematic reviews [8, 29]. Items were categorized into four groups: diagnosis, classification, treatment, and rehabilitation. Online surveys were generated to allow respondents to rate whether items should be included within minimum reporting requirements with five possible responses on a Likert [21] scale: “strongly agree”; “agree”; “neither agree nor disagree”; “disagree” or “strongly disagree”. A free-text comments section was included to allow for suggestions of modifications or additional items. The survey was piloted by three experts for face

Fig. 1 Flow of consensus process



validity, understanding and acceptability, resulting in minor modifications.

Establishing a consensus using Delphi methods

Delphi methods were used here to establish group consensus on whether items should be included in an international expert consensus document relating to PLC injuries [33]. A total of twenty-seven experts took part of whom 15 (55.5%) were from Europe, 3 (11.1%) were from North America, 3 (11.1%) were from South America, 3 (11.1%) were from Oceania, 2 (7.4%) were from Asia and 1 expert was from Africa (3.7%). All were internationally recognized experts in the management of PLC injuries (all the experts had more than 50 PLC reconstructions of experience).

Experts participated in three rounds of surveys between June and July of 2018. In the first round, surveys were analyzed, and participants were sent an anonymized summary of the results together with a second survey. In round one, items were categorized as ‘essential’ and retained for round two if over 70% of respondents agreed, and fewer than 20% disagreed. Items not meeting these criteria were discarded or modified according to responders’ suggestions. The second-round survey also included any new items suggested by experts in round one. In round two, participants were asked to re-score items and provide free-text comments. In round two, responses were analyzed retaining items if over 70% of respondents agreed on their inclusion, and fewer than 20% disagreed. Items retained after round two were considered in round three. Questionnaires were re-analyzed and the cycle repeated in round three. For consensus, defined a priori, items were included in the final consensus document if over 75% of respondents agreed, and fewer than 20% disagreed in the third round Delphi survey. Agreement in 75% of participants is the most frequently specified determination of a consensus for Delphi studies [4].

Results

Identification of items for inclusion in the first-round survey

Review of all data sources describing the management of PLC injuries generated 20 items for rating within the first-round survey. Items were categorized into four groups: diagnosis, classification, treatment, and rehabilitation.

Establishing consensus through the Delphi process

Twenty-seven experts completed all three rounds of surveys (100% response rate) within the allotted time. The results of each survey round are summarized in Table 1. Twenty-nine

Table 1 Summary of results at completion of each survey round in the Delphi process to establish an expert consensus on posterolateral corner injuries management

Delphi round	Responses	Total items included in survey	Items reaching consensus	Modifications or new items suggested
1	27	20	50%	15
2	27	35	67%	8
3	27	36	84%	0

of 36 (81%) individual items included within the final survey reached consensus (Fig. 2). The final list of statements reaching consensus is shown in Table 2.

Consensus findings

A summary of the consensus findings is outlined below.

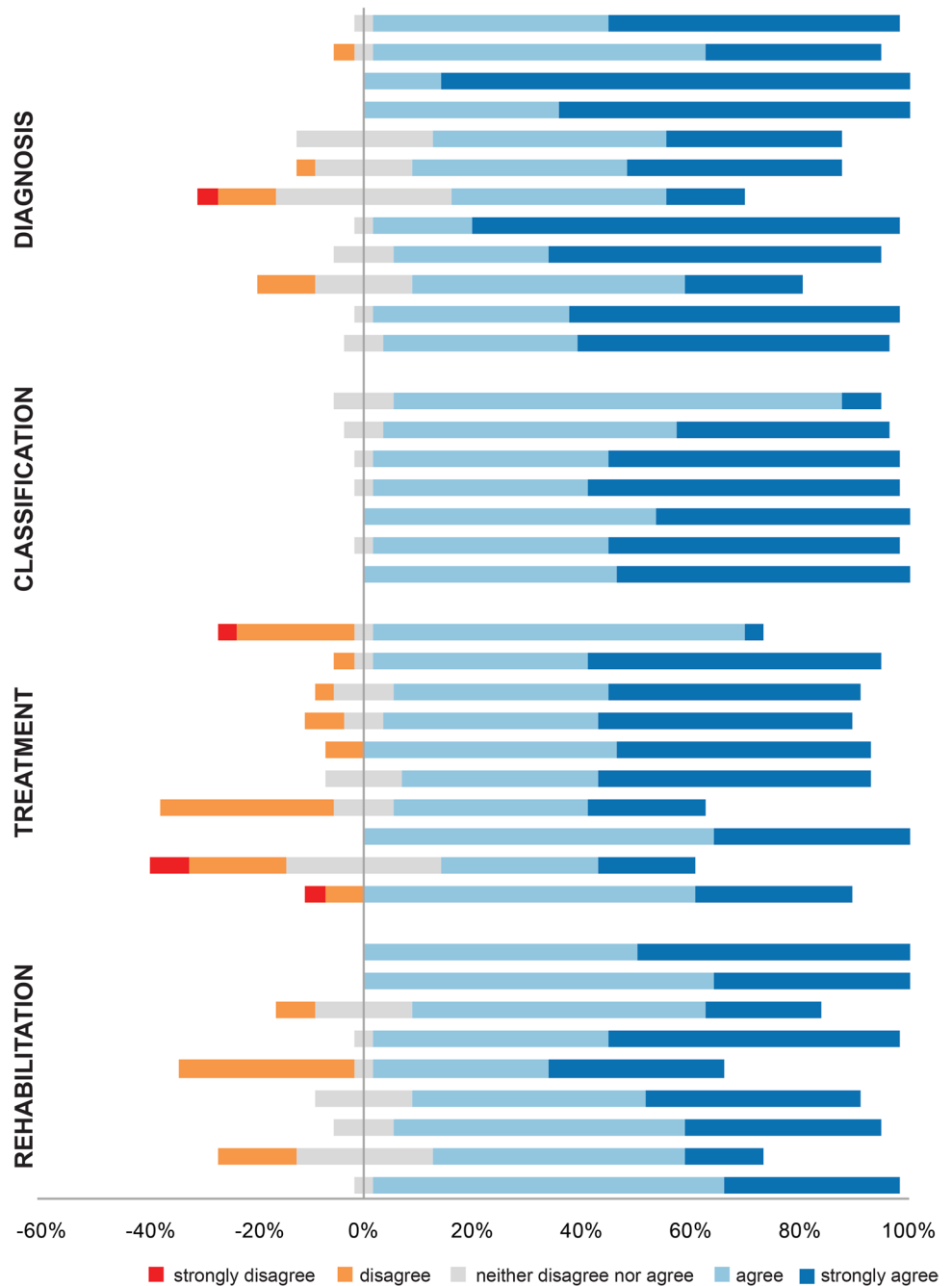
Diagnosis

PLC injuries are frequently associated with other knee ligamentous injuries and it is therefore important to accurately diagnose all concurrent ligamentous injuries. Clinical examination including special tests such as the varus stress test, the posterolateral drawer and the dial test are effective in diagnosing a posterolateral corner injury. Additionally, a positive dial test demonstrates external rotation laxity and is not pathognomonic for a PLC injury. Injury chronicity should be considered when interpreting physical examination findings.

In regard to imaging techniques, the expert group felt that magnetic resonance imaging should always be performed in the assessment of suspected acute posterolateral corner injuries. It was recognized that varus stress radiographs constitute an important diagnostic tool to assess the extent of injury as previously described [11, 13, 23]. Additionally, when baseline varus stress radiographs are obtained in the assessment of PLC injury, post-operative varus stress radiographs are a valuable tool to objectively assess PLC reconstruction stability. For chronic cases, long limb radiographs should be performed to evaluate for the presence of varus alignment which has been shown to be a detrimental factor in chronic PLC treatment outcomes.

It has been well documented that PLC injuries can be associated with vascular injuries [22, 24]. Further vascular assessment is indicated when there is clinical suspicion of vascular injury or when the ABI is less than 0.9 in the affected limb. Nerve conduction studies should be considered in the presence of neurological dysfunction on clinical examination in the chronic setting.

Fig. 2 Stacked leaning bar chart representing breakdown in agreement levels in the third round Delphi survey. Bars to the left of the Y axis indicate disagreement with bars to the right indicating agreement



Classification

The lack of a comprehensive, prognostic classification system was one of the concepts that experts agreed on. For instance, experts stated that current classification systems are too vague or too complicated to be implementable in daily practice and therefore improved classification systems are required for PLC injuries. Importantly, a future classification system should allow differentiation between isolated FCL and Popliteus tendon injuries and combined PLC injuries. Additionally, it should indicate the structures

injured, the type of injury (avulsion versus intrasubstance) and chronicity. Such classification system should also guide treatment and reflect prognosis.

Treatment

Factors that influence the timing of surgery include concurrent meniscal pathology, concomitant medical status, soft tissue compromise, and the presence of an associated neurovascular injury. The majority of the experts (85.7%) felt that acute posterolateral corner injuries should be

Table 2 Levels of agreement and disagreement in the items included in R3 survey

	% Disagreement	% Agreement
Diagnosis		
Clinical examination including special tests such as varus stress test, the posterolateral drawer and the dial test are effective in diagnosing a posterolateral corner injury	0.0	96.4
A positive dial test demonstrates external rotation laxity and is not pathognomonic for a PLC injury	3.6	92.9
PLC injuries are frequently associated with other knee ligamentous injuries and it is therefore important to accurately diagnose all concurrent ligamentous injuries	0.0	100.0
Magnetic resonance imaging should always be performed in the assessment of suspected acute posterolateral corner injuries	0.0	100.0
Varus stress radiographs constitute an important diagnostic tool to assess the extent of injury	0.0	75
When baseline varus stress radiographs have been obtained in the assessment of PLC injury, post-operative varus stress radiographs are a valuable tool to objectively assess PLC reconstruction stability	3.6	78.6
Instrumented measurements of laxity can be useful in determining lateral sided instability	14.3	53.6*
Long limb radiographs should be performed in cases of chronic PLC injury to evaluate for the presence of varus alignment	0	96.4
Injury chronicity should be considered when interpreting physical examination findings	0	89.3
A drive through sign is a reliable arthroscopic sign of posterolateral corner injury	10.7	71.4*
Further vascular assessment is indicated when there is clinical suspicion of vascular injury or when the ABI is less than 0.9 in the affected limb	0	96.4
Nerve conduction studies should be performed in the presence of neurological dysfunction on clinical examination in the chronic setting	0	92.6
Classification		
Current classification systems are too vague or too complicated to be implementable in daily practice	0.0	92.9
Improved classification systems are required for PLC injuries	0.0	89.3
Future classification systems should allow differentiation between isolated FCL and Popliteus tendon injuries and combined PLC injuries	0.0	96.4
A future classification system should indicate the structures injured, the type of injury (avulsion versus intrasubstance) and chronicity	0.0	100.0
A future classification system should guide treatment and reflect prognosis	0	96.4
Treatment		
There are indications for conservative management of posterolateral corner injuries in the acute setting	25.0*	71.43*
Factors that influence the timing of surgery include concurrent meniscal pathology, concomitant medical status, soft tissue compromise, and the presence of associated neurovascular injury	3.6	92.9
Acute posterolateral corner injuries should be surgically addressed within 2–3 weeks following injury	3.6	85.7
Individual posterolateral corner structures should be reconstructed only if injured, avoiding reconstruction of structures that are not damaged	7.1	85.7
An anatomic posterolateral corner reconstruction is the preferred technique when all primary PLC structures are injured	7.1	92.9
In chronic cases, varus malalignment should be corrected with a valgus producing high tibial osteotomy prior to, or at the time of PLC reconstruction	0.0	85.7
Common peroneal nerve neurolysis should be performed systematically when performing a PLC reconstruction	32.1*	57.1*
Hybrid procedures—reconstruction of primary structures (FCL, popliteus and popliteofibular ligament) and repair of secondary restraints (biceps avulsions, lateral capsule, iliotibial band avulsions) can yield satisfactory outcomes	0.0	100.0
Minimally invasive techniques (arthroscopic/mini open) have a role in the treatment of PLC injuries	25.0*	46.4*
Repair of primary PLC structures (FCL/popliteus tendon) is a valid treatment option in bone avulsions	10.7	89.2
Rehabilitation		
A sequential staged rehabilitation (range of motion, muscular endurance, strength, and finally power) is important for a successful outcome	0.0	100.0
The degree of injury and type of surgical treatment performed should be considered when formulating post-operative rehabilitation strategies	0.0	100.0
An early mobilization protocol (starting with range of motion on day 1) should be implemented to avoid arthrofibrosis	7.1	75.0

Table 2 (continued)

	% Disagreement	% Agreement
A knee brace should be utilized for at least 6 weeks following PLC surgery	0.0	96.4
Patients should remain non-weight-bearing or toe touch weight-bearing for a minimum of 6 weeks following PLC surgery	32.1*	64.2*
Return to sport after an isolated PLC reconstruction is not recommended before 9 months	0.0	82.1
Return to sport after an isolated PLC reconstruction should be based on objective functional tests	0.0	89.3
Comparative isokinetic assessment is an important tool that can help objectify return to sport	14.3	60.7*
Functional assessment before return to sports such as running with cutting movements or figure-of-eight running should be performed	0.0	96.4

*Represents items not reaching consensus

surgically addressed within 2–3 weeks following injury. In chronic cases, varus malalignment should be corrected with a valgus producing high tibial osteotomy prior to, or at the time of PLC reconstruction.

Concerning surgical treatment techniques, individual posterolateral corner structures should be reconstructed only if injured, avoiding reconstruction of structures that are not damaged. When all primary PLC structures are injured, an anatomic posterolateral corner reconstruction is the preferred technique. Hybrid procedures involving reconstruction of primary structures (FCL, popliteus and popliteofibular ligament) and the repair of secondary restraints (biceps avulsions, lateral capsule, iliotibial band avulsions) can yield satisfactory outcomes. Importantly, repair of primary PLC structures (FCL/popliteus tendon) is a potential treatment option only in bone avulsions.

Rehabilitation

Although the degree of injury and type of surgical treatment performed should be considered when formulating post-operative rehabilitation strategies, all experts agreed that a sequential staged rehabilitation protocol (range of motion, muscular endurance, strength, and finally power) is important for a successful outcome. For the immediate post-operative protocol, a knee brace should be utilized for at least 6 weeks following PLC surgery. Notably, early mobilization (starting with range of motion on day 1) should be implemented to avoid arthrofibrosis.

Return to sport was one of the most controversial topics in the expert consensus. However, experts agreed that after an isolated PLC reconstruction return to sport is not recommended before 9 months and should be based on objective functional tests. Functional assessment before return to sports such as running with cutting movements or figure-of-eight running should be performed.

Discussion

The most important finding of this study was that consensus among international experts on the management of posterolateral corner injuries was reached on the majority of the statements (81%). Significant agreement was reached on the importance of a comprehensive physical examination and objective diagnosis (and prognostic) tools such as stress radiographs and MRI. Furthermore, experts were in agreement that current classifications systems are too vague and/or complicated to be implementable and therefore there is a need for an updated system. There was heterogeneity reflected on the treatment (30%) and rehabilitation protocols (22%).

The differences in treatment and rehabilitation approaches seen by experts in the field delineate the importance of creating updated treatment and rehabilitation algorithms based on well-designed clinical trials. Most of the experts agreed that a prompt diagnosis and management is crucial for patients with PLC injuries, because improved clinical outcomes have been reported with PLC reconstructions performed within three weeks of injury [7]. Additionally, an objective assessment of lateral compartment structures was deemed to be important through MRI scans (which can be a useful modality in the diagnosis and pre-operative planning of acute PLC injuries) [5, 6, 16] and the use of varus stress radiography (also useful for chronic cases). Bilateral varus stress radiographs with a physician-applied force at 20° of knee flexion are obtained and have been reported to be highly reproducible [13, 18].

Importantly, a thorough neurovascular examination should be performed with careful evaluation of the common peroneal nerve because this nerve can sustain a traction injury in up to 15% of PLC-injured patients [14]. However, management of the common peroneal nerve was

not unanimous during the three rounds. To this point, the body of literature suggests that its management should be based on the severity and location of the nerve injury, timing of presentation, and associated injuries requiring surgical management [27]. Generally, the common peroneal nerve should be identified and released from the surrounding soft tissue during a reconstruction of the PLC to avoid neuropraxia or injury to the nerve, which can occur if the common peroneal nerve is trapped in soft tissue during post-operative swelling [25, 32].

Significant controversy endured the three rounds of surveys in other topics such as the role of conservative treatment. In this regard, animal studies have revealed the natural history of grade III PLC injuries, which do not heal in the majority of cases [10, 31]. The main reason for this is the bony anatomy of the lateral compartment, which consists of two convex surfaces, that creates an unstable articular congruency relative to the medial compartment [17]. Kannus [14] reported that the long-term results of non-operative management of grade II PLC injuries were acceptable, but those of grade III injuries were less than optimal. Persistent gross varus laxity and post-traumatic osteoarthritis were among the most frequent complications reported following non-operative management of grade III PLC injuries. This arthritic effect was further corroborated by animal models, which showed arthritic changes as early as six months after injury [10, 31].

In this consensus, the expert panel agreed that primary PLC components (FCL, popliteus tendon and PFL) should be reconstructed, while secondary structures can be repaired (hybrid construct). This is based on previous literature reporting inferior outcomes when primary PLC structures are repaired. Stannard et al. [34] evaluated outcomes of repair versus reconstruction after PLC injuries, and reported a 37% failure rate in the repair group versus 9% the reconstruction group [5]. In a similar study by Levy et al. [20], a 40% failure rate was reported in the repair group versus 6% in the reconstruction group. The panel agreed that the most appropriate technique to address PLC injuries was an anatomy-based, biomechanically validated PLC reconstruction.

Certain basic rehabilitation statements had substantial disagreement including weight-bearing status after surgery (32.1%) and the utility of isokinetic testing as a tool to help objectify return to sport (14.3%). Posterolateral corner injuries rarely occur in isolation, and therefore post-operative rehabilitation protocols are structured based on the concomitant soft tissue and osseous injury. To date there is only one prospective study assessing the feasibility of early weight-bearing for isolated FCL injuries (limited evidence exists on full PLC injuries). LaPrade et al. [15] demonstrated equivalent post-operative clinical outcomes using an early partial weight-bearing protocol and a non-weight-bearing protocol

following FCL reconstruction, both in isolation and in combination with ACL reconstruction.

The strengths of this consensus are that the Delphi methods used for this study are advantageous over group-based processes, including subject anonymity that can reduce the effects of dominant individuals [9]. Additionally, Delphi consensus statements conducted at a distance are as reliable as face-to-face panels [35] with further advantages including the possibility to complete this at the pace of each expert, being more flexible in their allotted time [12]. Importantly, this expert consensus statement fulfills established criteria for the reporting of Delphi studies [4], using a validated number of experts balanced from 21 different countries [1]. One hundred percent response rate across all three survey rounds highlights the commitment of experts to establish consensus on how to accurately diagnose, treat and rehabilitate PLC injuries. Nevertheless, this study is not without limitations. As with any other consensus statement, although the statements were created from a review of the literature, the modifications and suggestions presented are not directly derived from data but from expert opinions. Some of the presented statements could not be generalizable due to the lack of certain resources in all of their practices, such as stress radiographs or vascular studies.

Conclusion

In conclusion, this study has established expert consensus on the management of PLC injuries in the majority of the statements (81%) in regard to diagnosis, classification, treatment, and rehabilitation concepts. Further research is needed to develop updated classification systems, and better understand the role of non-invasive and minimally invasive approaches along with standardized rehabilitation protocols.

Funding No external funding was used.

Compliance with ethical standards

Conflict of interest P.E.G. receives board membership fees from the Spanish Arthroscopic Association and consultancy fees from Commed; and is an employee of Hospital Sant Pau, Barcelona, Spain. The rest of the authors have nothing to disclose.

Ethical Approval This study does not contain any studies with human participants performed by any of the authors.

References

1. Akins RB, Tolson H, Cole BR (2005) Stability of response characteristics of a Delphi panel: application of bootstrap data expansion. *BMC Med Res Methodol* 5:37

2. Chahla J, Kennedy NI, Cinque ME, Sanchez G, Logan C, Vopat BG et al (2018) Posterolateral corner injuries of the knee at the National Football League Combine: an imaging and outcomes analysis. *Arthroscopy* 34:687–692
3. Chahla J, Moatshe G, Dean CS, LaPrade RF (2016) Posterolateral corner of the knee: current concepts. *Arch Bone Jt Surg* 4:97–103
4. Diamond IR, Grant RC, Feldman BM, Pencharz PB, Ling SC, Moore AM et al (2014) Defining consensus: a systematic review recommends methodologic criteria for reporting of Delphi studies. *J Clin Epidemiol* 67:401–409
5. Geeslin AG, Geeslin MG, LaPrade RF (2017) Ligamentous reconstruction of the knee: what orthopaedic surgeons want radiologists to know. *Semin Musculoskelet Radiol* 21:75–88
6. Geeslin AG, LaPrade RF (2010) Location of bone bruises and other osseous injuries associated with acute grade III isolated and combined posterolateral knee injuries. *Am J Sports Med* 38:2502–2508
7. Geeslin AG, LaPrade RF (2011) Outcomes of treatment of acute grade-III isolated and combined posterolateral knee injuries: a prospective case series and surgical technique. *J Bone Jt Surg Am* 93:1672–1683
8. Geeslin AG, Moulton SG, LaPrade RF (2016) A systematic review of the outcomes of posterolateral corner knee injuries, part 1: surgical treatment of acute injuries. *Am J Sports Med* 44:1336–1342
9. Greenhalgh T, Wong G, Jagosh J, Greenhalgh J, Manzano A, Westhorp G et al (2015) Protocol—the RAMESES II study: developing guidance and reporting standards for realist evaluation. *BMJ Open* 5:e008567
10. Griffith CJ, Wijdicks CA, Goerke U, Michaeli S, Ellermann J, LaPrade RF (2011) Outcomes of untreated posterolateral knee injuries: an in vivo canine model. *Knee Surg Sports Traumatol Arthrosc* 19:1192–1197
11. Gwathmey FW Jr, Tompkins MA, Gaskin CM, Miller MD (2012) Can stress radiography of the knee help characterize posterolateral corner injury? *Clin Orthop Relat Res* 470:768–773
12. Holliday C, Robotin M (2010) The Delphi process: a solution for reviewing novel grant applications. *Int J Gen Med* 3:225–230
13. Kane PW, Cinque ME, Moatshe G, Chahla J, DePhillipo NN, Provencher MT et al (2018) Fibular collateral ligament: varus stress radiographic analysis using 3 different clinical techniques. *Orthop J Sports Med* 6:2325967118770170
14. Kannus P (1989) Nonoperative treatment of grade II and III sprains of the lateral ligament compartment of the knee. *Am J Sports Med* 17:83–88
15. LaPrade RF, DePhillipo NN, Cram TR, Cinque ME, Kennedy MI, Dornan GJ et al (2018) Partial controlled early postoperative weightbearing versus nonweightbearing after reconstruction of the fibular (lateral) collateral ligament: a randomized controlled trial and equivalence analysis. *Am J Sports Med* 46:2355–2365
16. LaPrade RF, Gilbert TJ, Bollom TS, Wentorf F, Chaljub G (2000) The magnetic resonance imaging appearance of individual structures of the posterolateral knee. A prospective study of normal knees and knees with surgically verified grade III injuries. *Am J Sports Med* 28:191–199
17. LaPrade RF, Griffith CJ, Coobs BR, Geeslin AG, Johansen S, Engebretsen L (2014) Improving outcomes for posterolateral knee injuries. *J Orthop Res* 32:485–491
18. LaPrade RF, Johansen S, Agel J, Risberg MA, Moksnes H, Engebretsen L (2010) Outcomes of an anatomic posterolateral knee reconstruction. *J Bone Jt Surg Am* 92:16–22
19. LaPrade RF, Wentorf FA, Crum JA (2004) Assessment of healing of grade III posterolateral corner injuries: an in vivo model. *J Orthop Res* 22:970–975
20. Levy BA, Dajani KA, Morgan JA, Shah JP, Dahm DL, Stuart MJ (2010) Repair versus reconstruction of the fibular collateral ligament and posterolateral corner in the multiligament-injured knee. *Am J Sports Med* 38:804–809
21. Likert R (1932) A technique for the measurement of attitudes. *Arch Psychol* 140:1–55
22. MacDonald P, Vo A (2015) Complications of posterolateral corner injuries of the knee and how to avoid them. *Sports Med Arthrosc Rev* 23:51–54
23. McDonald LS, Waltz RA, Carney JR, Dewing CB, Lynch JR, Asher DB et al (2016) Validation of varus stress radiographs for anterior cruciate ligament and posterolateral corner knee injuries: a biomechanical study. *Knee* 23:1064–1068
24. Moatshe G, Chahla J, Kruckeberg BM, Muckenhirn KJ, Brady AW, Cinque ME et al (2018) The influence of graft tensioning sequence on knee kinematics during bicruciate and posterolateral corner knee ligament reconstruction: a biomechanical study. *Am J Sports Med* 46(8):1863–1869
25. Moatshe G, Dean CS, Chahla J, Serra Cruz R, LaPrade RF (2016) Anatomic Fibular Collateral Ligament Reconstruction. *Arthrosc Tech* 5:e309–e314
26. Moatshe G, Dornan GJ, Loken S, Ludvigsen TC, LaPrade RF, Engebretsen L (2017) Demographics and injuries associated with knee dislocation: a prospective review of 303 patients. *Orthop J Sports Med* 5:2325967117706521
27. Mook WR, Ligh CA, Moorman CT 3rd, Leversedge FJ (2013) Nerve injury complicating multiligament knee injury: current concepts and treatment algorithm. *J Am Acad Orthop Surg* 21:343–354
28. Mook WR, Miller MD, Diduch DR, Hertel J, Boachie-Adjei Y, Hart JM (2009) Multiple-ligament knee injuries: a systematic review of the timing of operative intervention and postoperative rehabilitation. *J Bone Jt Surg Am* 91:2946–2957
29. Moulton SG, Geeslin AG, LaPrade RF (2016) A systematic review of the outcomes of posterolateral corner knee injuries, part 2: surgical treatment of chronic injuries. *Am J Sports Med* 44:1616–1623
30. Nannaparaju M, Mortada S, Wiik A, Khan W, Alam M (2018) Posterolateral corner injuries: epidemiology, anatomy, biomechanics and diagnosis. *Injury* 49:1024–1031
31. Pepin SR, Griffith CJ, Wijdicks CA, Goerke U, McNulty MA, Parker JB et al (2009) A comparative analysis of 7.0-Tesla magnetic resonance imaging and histology measurements of knee articular cartilage in a canine posterolateral knee injury model: a preliminary analysis. *Am J Sports Med* 37(Suppl 1):119s–124s
32. Serra Cruz R, Mitchell JJ, Dean CS, Chahla J, Moatshe G, LaPrade RF (2016) Anatomic posterolateral corner reconstruction. *Arthrosc Tech* 5:e563–e572
33. Stacey DBC, Barry MJ, Col NF, Eden KB, Holmes-Rovner M et al. (2011) Decision aids for people facing health treatment or screening decisions. *Cochrane Database Syst Rev* 10:CD001431
34. Stannard JP, Brown SL, Farris RC, McGwin G Jr, Volgas DA (2005) The posterolateral corner of the knee: repair versus reconstruction. *Am J Sports Med* 33:881–888
35. Washington DL, Bernstein SJ, Kahan JP, Leape LL, Kamberg CJ, Shekelle PG (2003) Reliability of clinical guideline development using mail-only versus in-person expert panels. *Med Care* 41:1374–1381

Affiliations

Jorge Chahla¹ · Iain R. Murray² · James Robinson^{8,9} · Koen Lagae¹⁰ · Fabrizio Margheritini¹¹ · Brett Fritsch¹² · Manuel Leyes¹³ · Björn Barenius¹⁴ · Nicolas Pujol^{15,16} · Lars Engebretsen¹⁷ · Martin Lind¹⁸ · Moises Cohen¹⁹ · Rodrigo Maestu²⁰ · Alan Getgood²¹ · Gonzalo Ferrer²⁸ · Silvio Villascusa²⁶ · Soshi Uchida³¹ · Bruce A. Levy²³ · Richard Von Bormann²⁴ · Charles Brown²⁵ · Jacques Menetrey²⁹ · Michael Hantes³⁰ · Timothy Lording³² · Kristian Samuelsson^{5,33} · Karl Heinz Frosch^{6,7} · Juan Carlos Monllau²⁷ · David Parker¹² · Robert F. LaPrade²² · Pablo E. Gelber^{3,4}

James Robinson
jrrobinson@doctors.org.uk

Koen Lagae
kclagae@knee.be

Fabrizio Margheritini
mararthro@gmail.com

Brett Fritsch
brett@brettfritsch.com.au

Manuel Leyes
leyesm@yahoo.com

Björn Barenius
bjorn.barenius@gmail.com

Nicolas Pujol
nicolaspujol1@yahoo.fr

Lars Engebretsen
lars.engebretsen@medisin.uio.no

Martin Lind
martinlind@dadlnet.dk

Moises Cohen
drmoisescohen@gmail.com

Rodrigo Maestu
rmaestu@intramed.net

Alan Getgood
agetgoo@uwo.ca

Gonzalo Ferrer
dr.gonzaloferrer@gmail.com

Silvio Villascusa
silvio.dr@gmail.com

Soshi Uchida
soshisports1966@gmail.com

Bruce A. Levy
levy.bruce@mayo.edu

Richard Von Bormann
drrichard@ctorth.com

Charles Brown
charliebrowngoestosa@yIanhthoern.caotimonal

Jacques Menetrey
jacques.menetrey@lacolline.ch

Michael Hantes
hantesmi@otenet.gr

Timothy Lording
tlording@iinet.net.au

Kristian Samuelsson
kristian@samuelsson.cc

Karl Heinz Frosch
k.frosch@asklepios.com

Juan Carlos Monllau
jmonllau@parcdesalutmar.cat

David Parker
dparker@sydneyortho.com.au

Robert F. LaPrade
rlaprade@thesteadmanclinic.com

¹ Rush University Medical Center, 1611 W Harrison, Suite 300, Chicago, IL 60612, USA

² Department of Orthopaedic Surgery, The University of Edinburgh, Edinburgh, UK

³ Department of Orthopaedic Surgery, Hospital de la Sta Creu i Sant Pau, Universitat Autònoma de Barcelona, Barcelona, Spain

⁴ ICATME-Hospital Universitari Dexeus, Universitat Autònoma de Barcelona, Barcelona, Spain

⁵ Department of Orthopaedics, Sahlgrenska University Hospital, Sahlgrenska Academy, Gothenburg University, Gothenburg, Sweden

⁶ University Medical Center Hamburg-Eppendorf, Hamburg, Germany

⁷ Asklepios Clinic St. Georg, Hamburg, Germany

⁸ Avon Orthopaedic Centre, Bristol, UK

⁹ International Knee and Joint Center, Abu Dhabi, UAE

¹⁰ Monica Hospitals, Antwerp, Belgium

¹¹ University of Rome Foro Italico, Rome, Italy

¹² Sydney Orthopaedic Research Institute, Sydney, Australia

¹³ Clínica CEMTRO, Madrid, Spain

¹⁴ Stockholm South Hospital, Karolinska Institutet, Stockholm, Sweden

¹⁵ Centre Hospitalier de Versailles, Le Chesnay, France

¹⁶ Oslo University Hospital, Oslo, Norway

¹⁷ Oslo Sports Trauma Research Center, Oslo, Norway

¹⁸ Aarhus University Hospital, Aarhus, Denmark

¹⁹ Universidade Federal de São Paulo, São Paulo, SP, Brazil

²⁰ Centro de tratamiento de enfermedades articulares, Buenos Aires, Argentina

-
- ²¹ Fowler Kennedy Sports Medicine Clinic, London, ON, Canada
- ²² The Steadman Clinic, Vail, CO, USA
- ²³ Mayo Clinic, Rochester, MN, USA
- ²⁴ Cape Town Sports & Orthopaedic Clinic, Cape Town, South Africa
- ²⁵ International Knee and Joint Centre, Abu Dhabi, UAE
- ²⁶ Hospital La Fraternidad Habana, Madrid, Spain
- ²⁷ Parc de Salut Mar, UAB, Barcelona, Spain
- ²⁸ Hospital Clinico Mutual de Seguridad, Santiago, Chile
- ²⁹ University Hospitals of Geneva, Geneva, Switzerland
- ³⁰ University of Thessalia, Larissa, Greece
- ³¹ Wakamatsu Hospital for the University of Occupational and Environmental Health, Kitakyushu, Japan
- ³² Melbourne Orthopaedic Group, Melbourne, Australia
- ³³ Nanometer Structure Consortium, Lund University, Lund, Sweden