

# Allograft Meniscus Transplantation: A Current Review

Joan C. Monllau, MD, PhD,\*† Gemma González-Lucena, MD,\*  
Pablo E. Gelber, MD, PhD,\* and Xavier Pelfort, MD†‡

**Abstract:** Meniscal tissue's ability to heal has been shown to be limited. Until recently, orthopedic surgeons treating patients who had undergone a meniscectomy had few options available to treat the persistent pain sometimes associated with it and the subsequent early joint degeneration. This was true except in cases of limb malalignment. Meniscal allograft transplantation was introduced in the eighties to deal with the matter at hand and tends to produce good mid-term results when used on patients who have undergone meniscectomy. This article explores the history, indications, technique, results, and current concerns relative to this procedure. The investigators' perspective derived from having carried out more than 100 allograft meniscal transplantations over the past 9 years is also laid out.

**Key Words:** allograft, meniscus, transplantation, arthroscopy, knee

(*Tech Knee Surg* 2010;9: 107–113)

## HISTORIC PERSPECTIVE

The meniscus consists of a semilunate wedge-shaped fibrocartilage tissue mass that increases the congruence of the tibiofemoral joint. It plays an important role in shock absorption, load transmission, lubrication, and stabilizing the knee joint. At the beginning of the twentieth century, King showed the degenerative changes that occurred after meniscectomy in an experimental dog model.<sup>1</sup> Some years later, Fairbank described the same arthritic changes that can be seen in a meniscectomized knee in humans.<sup>2</sup> Several investigators have since confirmed Fairbank findings.<sup>3–5</sup> The changes are owing to the loss of some biomechanical functions of the meniscus itself.<sup>6,7</sup> It has since been shown that the loss of meniscal tissue dramatically increases the contact forces in the meniscectomized compartment.<sup>8</sup>

Nevertheless, total meniscectomy was the treatment of choice for a meniscal rupture for a long period of time. It provided excellent clinical results on the short-term, even though the long-term results were not so good owing to cartilage damage. Hence, more conservative techniques such as partial meniscectomy and suture of the meniscus have increasingly been used especially since the introduction of arthroscopy. However, few meniscal injuries fulfill the accepted criteria for adequate meniscal repair.

More recently, there has been a breakthrough in the treatment of an injured meniscus. It attempts to replace the damaged tissue and to prevent progressive deterioration of the joint. To this end, meniscal allograft transplantation (AMT) has been introduced in clinical practice. The transplantation of a meniscus as a free graft was developed in Germany in the

mid 80's.<sup>9</sup> However, 2 surgical teams in North America experimented with massive fresh osteochondral allografts, including the corresponding meniscus, to reconstruct posttraumatic defects of the tibial plateau 1 decade earlier.<sup>10,11</sup> The viability and survival of the meniscal graft has been shown overtime. However, 1 of the main goals of AMT such as its possible chondroprotective effect remained unproven for a long period of time. Recently, some long-term reports give credence to the prophylactic effect of the transplant.<sup>12,13</sup> Notwithstanding, several features of the graft itself and aspects relative to the transplantation procedure are still a matter of controversy. Graft characteristics, preservation, sizing, and immunogenicity are the most hotly debated issues.

## INDICATIONS/CONTRAINDICATIONS

There is general agreement as to the indication criteria for AMT. The most common indication is compartmental knee pain owing to a prior meniscectomy in a patient not eligible for prosthetic replacement. The same patient must also show limited cartilage joint damage in an otherwise well-aligned and stable knee. If these 3 conditions are conveniently addressed earlier or at the same time, AMT may also be indicated.

Absolute contraindications include general inflammatory or systemic diseases and obesity (defined by a BMI of more than 30) and immunodeficiency. Some localized conditions such as any kind of arthritis (septic, metabolic, or inflammatory), and synovial diseases are also considered contraindications. A relative contraindication is its use on skeletally immature patients because the ability of the transplanted meniscus for growth is unknown. Advanced degenerative joint disease has also been considered a contraindication, although some investigators have observed good outcomes in this particular population.<sup>14,15</sup>

## PREOPERATIVE PLANNING

After a thorough physical examination, a routine radiographic study should be done. This includes a long standing AP view of both inferior extremities to assess lower-limb alignment, a nonweight-bearing 30 degrees flexion lateral radiograph and 45 degrees flexion weight-bearing postero-anterior views of both knees to assess any early joint line collapse. An MRI is done to confirm the loss of meniscal tissue and the status of the cartilage and any associated condition.

## Graft Sizing

The use of a standard radiographic or CT scan measures and reasonably good morphometric measure correspondence between donor and recipient knees will prevent any sizing mismatch. The investigator's preferred method for graft sizing uses plain radiographs, calculating the mediolateral size of the menisci on the AP view by measuring from the medial or lateral tibial epiphyseal margin to the respective tibial eminence. Regarding the anteroposterior meniscus size, it corresponds to

From the \*Hospital de la Santa Creu i Sant Pau, Universitat Autònoma de Barcelona (UAB); †IMAS: Hospitals Mar-Esperança; and ‡ICATME–Institut Universitari Dexeus, UAB, Barcelona, Spain.

Address correspondence and reprint requests to Joan C. Monllau MD, PhD, St Antoni M<sup>a</sup> Claret 167, 08025 Barcelona, Spain. E-mail: JMonllau@santpau.cat.

Copyright © 2010 by Lippincott Williams & Wilkins

70% of the tibial plateau sagittal length on the lateral view for the lateral meniscus, whereas it is 80% for the medial meniscus.<sup>16</sup> Both measures are taken after correcting the magnification.

### Allograft Preservation and Storage Technique

These distinct methods of preserving allografts have been used since the introduction of AMT:

- Freeze Drying or Lyophilization: Dehydration as a meniscus preservation technique is no longer being used owing to the fact that it has proven to increase the risk of meniscal size retraction or shrinkage.<sup>9</sup>
- Deep or Fresh Frozen: The samples are simply frozen, without processing, at  $-80^{\circ}\text{C}$ , making the procedure simple and inexpensive. Although the procedure destroys the cells of the graft, it has been said that it preserves the collagen architecture. However, a recent study suggested that this process might alter the meniscus' collagen net and thereby compromise the future nutrition of the graft.<sup>17</sup>
- Cryopreservation: This is probably the most commonly used meniscal graft preservation method. Cryopreservation freezes the graft at  $-180^{\circ}\text{C}$  with the addition of glycerol or dimethyl sulfoxide as antifreezing agents. This method is believed to preserve cell membrane integrity and donor fibrochondrocyte cell viability. Furthermore, a recent work showed that cryopreservation is able to preserve the meniscal ultrastructure. Therefore, an allograft stored in that way would not have altered biomechanical properties even though its cellular viability is highly unpredictable.<sup>18</sup>
- Fresh and viable: Fresh menisci, harvested from multiorgan donor, are not a common alternative. The grafts must be used within a short period of time so as to maintain viability and there are concerns relative to the transmission of infectious diseases. To obtain viable menisci, the prior incubation of the fresh meniscus in recipient serum for 15 days is required. Although logistically complex, these choices are much more attractive in terms of functional cell survival.<sup>19</sup>

Several secondary sterilization techniques were used in the past.  $\gamma$  irradiation that used to be the most common, has been abandoned owing to its deleterious effects on the graft's mechanical properties when applied at the dose needed to inactivate viruses.<sup>20</sup>

### TECHNIQUE

Several techniques have been described for AMT. The initial series were done through an open arthrotomy.<sup>9-11,21</sup> This usually requires detachment of the collateral ligament femoral insertion. As arthroscopic procedures became more feasible, so did the arthroscopic implantation of meniscal allograft. It has been suggested that it reduces surgical morbidity, avoids collateral ligament injury, and facilitates early rehabilitation. Furthermore, an arthroscopic technique would seem preferable because of improved visualization of the intraarticular environment needed to pass the graft and secure it and the treatment of associated injuries. Nevertheless, there are currently no clinical trials comparing the 2 techniques.

The key objective of the AMT is the correct anatomic positioning and peripheral fixation of the graft. Although it may be easier to secure the graft by soft tissue alone, cadaver model research indicates that superior transmission of load occurs when fixing the meniscal horns of the graft with bone plugs.<sup>22</sup> When using bony fixation, there is also a debate as to whether to use bone plugs attached to the anterior and posterior horns or simply a bone bridge. The former allows a less invasive technique and might preserve the tibial eminence. However, it is technically unforgiving owing to the fact that

minimal misplacement of the tibial tunnels may lead to improper functioning of the meniscal graft.<sup>23</sup>

### Patient Positioning

A thigh tourniquet, inflated after the sterile field is prepared, is strongly recommended. Positioning is up to the surgeon. Placing the patient supine was found to be easier for the investigators. In case of a medial AMT, both legs are left hanging free at 90 degrees flexion. In case of a lateral AMT, the contralateral limb is placed in extension. It allows for the figure-of-4-position without the help of an assistant.

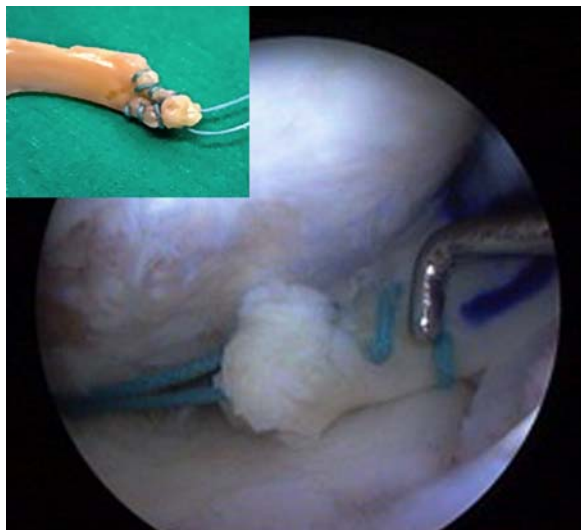
### Graft Preparation

The residual synovial tissue is dissected from the allograft at the meniscosynovial junction with a scalpel. The upper side of the meniscus and the union between the middle and posterior thirds are marked with a blue skin marker. This will help in avoiding improper placement of the graft during insertion. In the soft tissue fixation technique, either horns can be left unsutured or they can be sutured in a whipstitch manner if transtibial fixation is preferred (Fig. 1). The investigators used the latter in their first series of AMT.

A suture is passed at the junction between the posterior horn and the body of the meniscus in which the pencil mark had been made. This will greatly help in introducing the prepared graft into the joint. This suture is first retrieved from the posterolateral or posteromedial corner with an outside-in technique and pulled when the graft is being introduced into the joint. Further enlargement of the corresponding anterior portal to accommodate the surgeon's finger makes introduction of the graft easier.

### Arthroscopic Procedure

A routine diagnostic arthroscopy is done through a standard anterolateral viewing portal. A convenient medial portal is then established depending on the compartment to be transplanted. The remaining meniscus is debrided to get a stable rim and guarantee a good blood supply. It is important



**FIGURE 1.** Arthroscopic view of a medial meniscus allograft being introduced in the joint. The suture in the posterior horn is used to pull the meniscus into place.

not to eliminate the entire meniscal rim as it may help the suturing and limit later allograft extrusion. For that purpose, the investigators recommend the use of high frequency or radiofrequency trephination. Radiofrequency creates an area of synovial necrosis adjacent to the graft that is promptly substituted by a newly formed and more vascular synovial layer that invades the allograft.<sup>24</sup>


The tibial spine can be flattened with a burr, if the posterior horn attachment site is not properly visualized.

### Bone Fixation

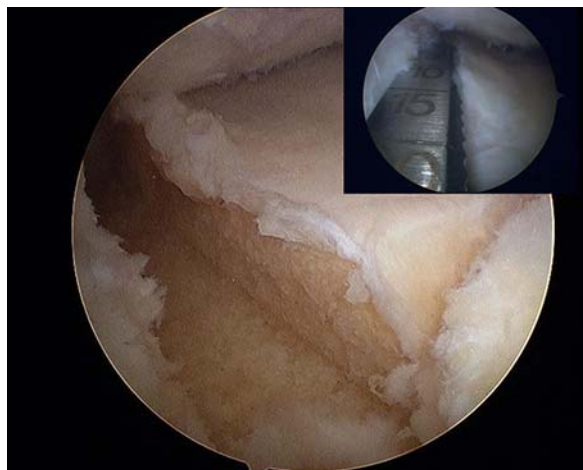
If a bone plug technique is to be used, exact positioning of the tibial tunnels for both meniscal horns is mandatory. As well described by Kohn and Moreno, they must be placed at the anatomic insertion sites.<sup>25</sup> Furthermore, it must be taken into account that there is great variability in medial meniscus anterior horn insertion types<sup>26</sup> and these variants must be respected when replacing the original meniscus. The tibial tunnels are drilled with the help of a standard or modified ACL tibial guide. Bone plugs and meniscal horns, when the allograft does not include bone and a transtibial fixation is used, are secured tying the sutures one to each other on the tibial cortex.

The bone bridge technique better preserves the native distance between horns and eliminates the risk of their incorrect placement (Fig. 2). In contrast, it is a more invasive technique because it affects tibial eminence integrity and resects more bone. The bone bridge procedure requires the creation of a trough in the tibial plateau using the bridge-in-slot technique.<sup>27</sup> In this technique, a guide pin connecting the anterior and posterior horns is followed by a drill and finally shaped with a 7 or 8-mm width box cutter to simply create the trough (Fig. 3). The same width and length matched size must be obtained with the graft. The instrumentation (Meniscal Transplant Set, Stryker Orthopaedics, Mahwah, NJ 07430, USA) is brought into the joint creating a lateral or medial portal just in line with the desired position of the planned trough. The so-called *keyhole* technique, which creates the cross-section of the bridge such as a keyhole, can optionally be used. The graft must be placed in its bed simply by sliding. The bone bar can be fixed with interference screws or left alone, as the investigators do, assuming that the bar is kept in place by the joint congruence.

Although medial meniscus transplantation is more commonly done with bone plugs, most investigators advocate carrying out AMT in the lateral meniscus with the bone bridge technique. It is more appropriate as the distance between the horns of the lateral meniscus is typically less than 1 cm.



**FIGURE 2.** Bone bridge meniscus allograft. The sizing block helps in achieving the desired graft fit before insertion in the joint.

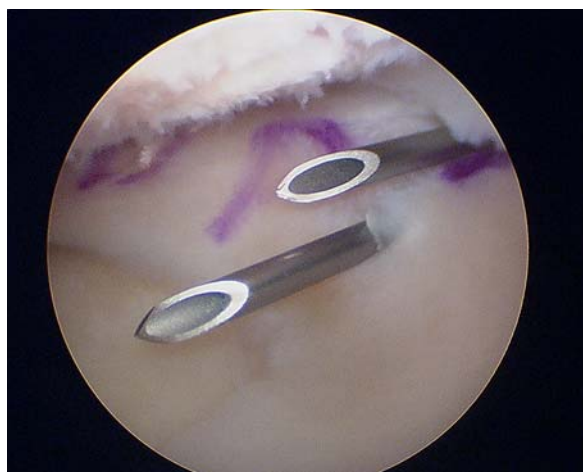


**FIGURE 3.** Arthroscopic view of the lateral tibial plateau in which a trough was created for a bone bridge allograft transplantation. In the upper right hand corner, arthroscopic view showing the rasp hand tool being used to create the slot.

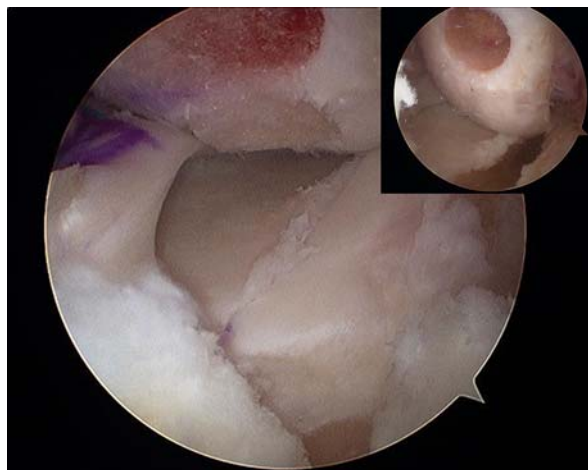
Therefore, tibial tunnel communication and a consequent compromised fixation of the horns could result if a bone-plug technique is used. The medial meniscus can also be transplanted with a bone bridge technique, but this requires careful placement so as not to alter the ACL tibial insertion. Furthermore, interference between bone troughs can occur if an ACL reconstruction is to be associated at the same time.

Finally, all-inside (FasT-Fix Suture System, Smith & Nephew, Inc., Andover, MA 01810, USA) or inside-out suturing (SharpShooter Tissue Repair System, ReGen Biologics, Redwood City, CA 94063, USA) is done at the posterior horn and body of the meniscus allograft. Then again, the anterior horn can be better fixed with an outside-in technique using a couple of 18 gauge spinal needles (Fig. 4).

An intraarticular drain can optionally be used. Nevertheless, it is the investigators' opinion that some residual hemarthrosis might enhance the meniscal healing process. The lower limb is finally placed in an immobilizer with a simple dressing to make it easy to apply an ice-pack.



**FIGURE 4.** Arthroscopic view of a medial allograft transplantation. The anterior horn of the meniscus is fixed with an outside-in technique using 2, 18-gauge spinal needles.



**FIGURE 5.** Arthroscopic view showing a bone bridge allograft transplantation and a concomitant outerbridge grade IV chondral lesion in the lateral femoral condyle. They were both addressed at the same time. In the upper right hand corner, the same knee after meniscal and chondral bed preparation.

### Combined or Additional Procedures

Chondral injuries are commonly encountered in these kinds of patients and its treatment is as important as the transplantation (Fig. 5). The surgical option depends on the size, depth, and localization of the lesion and the surgeon's experience. However, it is likely that those treatment modalities that include bone marrow stimulation are more appropriate as they may create an adequate biologic environment for both the cartilage and the transplant to heal.

Malalignment is thought to cause abnormal loading on the meniscal allograft that might produce early graft failure.<sup>28</sup> In contrast, by helping the ACL in resisting anterior translation, the meniscus is known to be an important secondary stabilizer of the knee. Therefore, either an osteotomy or a ligament reconstruction has to be done earlier as a staged procedure or at the time of the transplantation when considering an AMT under these circumstances.

For the currently cited series, the unstable knees were addressed at the same time as the meniscus transplant as both surgical techniques do not interfere with each other and the rehabilitation protocols are about the same. Nevertheless, there can be some interference that prevents the ACL tibial tunnel from being placed at the most appropriate site when using a bone bar technique. Such being the case, a staged procedure would be recommended. However, ACL reconstruction should be completed once the bone bar is radiologically healed because knee instability might be detrimental to the graft.

With regards to the malalignment, the issue is the difficulty in determining whether transplantation or osteotomy is more important in achieving pain relief as outlined by Cameron and Saha in their early report.<sup>14</sup> In the investigators' experience, this procedure has been always done in 2 stages. First the realignment is done; regularly by means of a high tibial osteotomy in cases of a varus knee and by femoral osteotomy in cases of valgus knee. If there was still any residual pain after good correction of the misalignment, the AMT was done. This approach can be more disabling for the patient as 2 surgical procedures have to be done in a relatively short period of time. However, we will be able to ascertain the

patients who really do need the transplantation and the actual role this procedure plays by carrying out this staged procedure.

### RESULTS

AMT has turned out favorably and shown to provide significant pain relief and functional improvement on a short and medium-term basis. Few series with long-term results exist in the literature and it is difficult to compare those because of the combination of procedures used. The limitations in comparisons also include graft preservation methods, fixation techniques, and outcome evaluation criteria. Clinical evaluation does not allow reliable assessment of the status of the allograft and both second-look surgeries and MRI have been used to carry out a more objective evaluation.<sup>29</sup>

Healing of the graft to the periphery, compartmental pain relief and functional improvement are among the most common findings in the first short-term reports on AMT. However, the potential chondroprotective effect of this procedure is difficult to establish as most of the studies have no control groups or are nonrandomized.

In a recent clinical trial review, the series analyzed provided successful outcome data for over 60% (12.5 to 100%) of their patients.<sup>29</sup> However, favorable results are observed in 88% of cases in a selective analysis of the more recent studies.<sup>30</sup> Potential causes for this improvement can include a refinement in the selection of patients, graft processing, and preparation and the surgical technique.<sup>31</sup>

Meniscal shrinkage has been a cause of concern as the introduction of AMT. At an average of 14 months post-operatively, Milachowski et al<sup>9</sup> found a trend toward shrinkage and failure in their lyophilized grafts when compared with the deep-frozen grafts. At 14 years, patients with lyophilized grafts had worse results, with shrinkage on second-look surgery and altered signal on MRI in all cases whereas the fresh-frozen group compared similarly with a control group with no meniscal injury.<sup>12</sup> Similarly, Stollsteimer followed 23 cryopreserved allografts for 1 to 5 years. The MRI's done showed the allografts shrinking an average 37% (0 to 69%). This size loss phenomenon was not correlated with poor clinical results.<sup>32</sup>

Another cause of concern for the orthopedic surgeons is the way that the allograft is fixed. Experimental studies have shown that secure anatomic fixation of bone plugs is required to restore normal contact mechanics for meniscal allografts and prevent meniscal extrusion.<sup>21</sup> However, favorable outcomes with both bony and soft tissue fixation of the meniscal horns have been found in clinical settings.<sup>13,14</sup> The aforementioned finding suggests that both systems are secure.

As mentioned earlier, uncorrected limb malalignment and ligamentous instability have been related to transplant failure<sup>21,33</sup> and should be considered a relative contraindication for the procedure and be corrected earlier or during the same surgery. In contrast, studies including combined procedures limit an exact assessment of the transplant's effects. Cameron obtained favorable results carrying out 34 osteotomies and 12 ACL reconstructions combined with meniscal allografts in a cohort of 63 patients.<sup>14</sup> Verdonk et al<sup>13</sup> published a follow-up of at least 10 years of 42 allografts in which greater functional improvement was achieved in a subgroup of 11 patients with a medial transplant in combination with high tibial osteotomy.

A tendency toward obtaining better results on lateral rather than medial allografts can be seen in the literature. Successful outcomes were achieved in 72% of the medial and

84% of the lateral allografts in Verdonk long-term series. In stable knees, no differences have been shown between medial and lateral allograft survival rates.<sup>13</sup>

Long-term series (>10 y) show, both functional and radiologic outcomes of deterioration overtime. Despite this, a majority of the patients maintain improved scores in comparison with the preoperative state. However, the chondroprotective effect of the AMT is yet to be established. Some investigators,<sup>12,32–34</sup> reported joint space narrowing in their series, in even up to 75% of the cases at final follow-up<sup>34</sup> but without clear correlation between degenerative changes and clinical results. In contrast, no progressive joint space narrowing was found radiographically in 34 fresh-frozen allografts at 2.9 years follow-up.<sup>35</sup> Similar results were reported by Garret and Stevenson,<sup>21</sup> van Arkel and De Boer<sup>33</sup> and Rath et al.<sup>36</sup> Verdonk et al<sup>13</sup> published a follow-up of at least 10 years with radiologic imaging from their first 42 allografts. The joint space remained stable in 41% and Fairbank changes did not progress in 28%. Interestingly enough, no significant correlations were found between any of the measured radiologic or MRI parameters and clinical outcome subscales.

### COMPLICATIONS

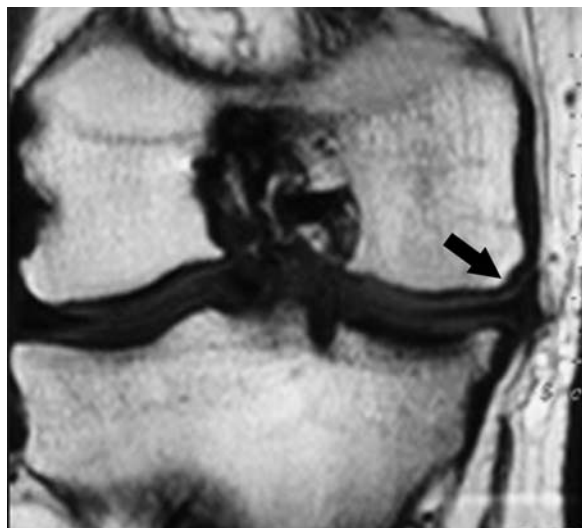AMT is frequently associated with complications that can be grouped into 3 different categories. In the first group, there are the usual complications associated with any surgical procedure; infection and neurovascular injury being the most serious. Septic arthritis and wound complications are rarely seen after either an open or arthroscopically assisted ATM.

The second group is related to those described after an allograft tissue transplant. It is known that the meniscus allograft may elicit some immune response. Rodeo et al<sup>37</sup> reported the presence of B lymphocyte and cytotoxic T-cells in the meniscal allograft at some time after transplantation. Their presence is thought to be owing to exposure to class I and II HLA antigens from dead synovial and endothelial cells. This response is usually subtle and has also been suggested as a possible cause of meniscal shrinkage.<sup>38</sup> Furthermore, if the graft also has bone attached to it, this bone would theoretically add more immunogenicity (ie, ABO antigens).<sup>39</sup> However, there is only 1 report in the literature of frank rejection of a meniscal allograft in human beings.<sup>40</sup>

Disease transmission is a second complication associated with AMT. Although careful and meticulous screening is done in most countries, there is generally a “window” through which infections may go undetected in the donor. Nevertheless, no cases of virus transmission have been communicated and only a few bacterial infections have been reported.<sup>32</sup>

The third group is related to the meniscal transplant itself and is not frequent. It includes arthrofibrosis, loss of bone plug or bone block fixation, detachment of the meniscus from the bone block, meniscal tear or failure to heal to the periphery, continued or progressive pain, or progression of degenerative joint disease. Graft tearing may be considered the most commonly seen complication. It has been reported in as many as 8.2% of the cases<sup>30</sup> and resulted in a reoperation rate of up to 26% of the patients in 1 series.<sup>32</sup>

Failure to heal at the posterior horn was the most common complication in our first series of AMT's without bone blocks. This finding has also been documented by others and indeed the type of fixation may have played a role in these failures. To avoid this complication, some investigators have advocated the



**FIGURE 6.** Coronal MRI view of an allograft transplantation 2 years after index surgery. Some degree of allograft extrusion (black arrow) can be seen.

use of bone block fixation. From the clinical point of view, there is no proof of a substantially better outcome using this technique to date.

Another frequently reported complication is allograft extrusion (Fig. 6). It is a phenomenon commonly seen in the natural history of degenerative knee joint disease.<sup>41</sup> However, meniscal allograft extrusion tends to be stable over the long term and a clear clinical relevance has not been proven to exist.<sup>42</sup>

Finally, allograft shrinkage is a graft size reduction process that ends in a smaller than expected meniscus. Meniscal shrinkage has been thought to be related to the use of lyophilized grafts. Recently, it has also been suggested that other factors might be involved.<sup>17</sup> The shrunken meniscus has impaired biomechanical properties,<sup>9</sup> but again no clear correlation with clinical findings has been found.

### POSTOPERATIVE MANAGEMENT

Owing to the lack of controlled studies relative to postoperative management after AMT, most of the investigators follow meniscal-suturing protocols. Nevertheless, a wide range of different postoperative treatments can be found in the literature.

There are some controversies regarding weight bearing. Some investigators allow immediate unlimited knee loading with the knee blocked in full extension.<sup>32,43</sup> They suggested that weight bearing compresses the bone block and might lead to faster bone integration. Furthermore, most animal studies allow immediate full-weight bearing and they do not seem to compromise the graft tissue.<sup>44,45</sup> In contrast, Fritz et al<sup>46</sup> recommended nonweight bearing for the first 6 postoperative weeks along with maintaining the lower limb in full extension. Our approach is to allow limited range of motion for the first 3 weeks because meniscal movement is minimal from 0 to 60 degrees of knee flexion.<sup>47</sup> Further flexion of the knee causes the meniscus to be displaced anteriorly, and it causes the posterior sutures to be pulled from the capsule. Owing to concerns regarding damage to the graft or its fixation during the early stage of postoperative revascularization, no weight

bearing is allowed for the first 3 to 4 weeks. Continuous passive motion and supervised physical therapy start during the first week of surgery; emphasizing knee extension, swelling and pain control, isometric quadriceps contractions, and passive and active motion. After those 3 to 4 weeks, the next postoperative step leads to further flexion to 90 degrees and progressive weight bearing, closed-chain kinetic exercises, and stationary biking. Full weight bearing is the goal at 6 to 8 weeks postoperatively. Straight line running is typically encouraged at 4 to 6 months.

Although there is no consensus with regards to the timing of return to forced flexion, pivoting, and strenuous activities, 6 to 12 months would seem a reasonable schedule based on the biology of meniscal healing and the available literature. Nevertheless, strenuous activity cannot be recommended as the behavior of transplanted menisci under repetitive high-impact activity is unknown. Research into understanding how load influences graft survival and its fixation sites is required. Until this data is available, athletic activity should be limited to light sports. It is imperative that the patient be made aware of such limitations before the transplantation and understand the currently “salvage” nature of the procedure.

### POSSIBLE CONCERNS, FUTURE OF THE TECHNIQUE

An important issue in meniscal substitution is the proper timing of the procedure. It has been suggested that meniscal allografts implanted in advanced degenerative knees ultimately fail owing to abnormal biomechanics, rough joint surfaces, and destructive enzymes. If the aim of AMT is to reduce degenerative changes of articular cartilage, it should be done as soon as possible after meniscectomy. As most of the patients have no symptoms in the first years after meniscectomy and a prophylactic transplant is nowadays not recommended, the question is how early to do it. This is owing to the fact that better results are observed in patients without advanced joint degeneration. An objective indicator is needed for early detection of degenerative changes before significant cartilage injury has occurred. In the future, analysis of collagen or proteoglycan breakdown products and metalloproteinase activity in the synovial fluid of knee joints may provide early evidence of cartilage breakdown.

Currently, the meniscal allograft is accepted as being a matrix structure in which revascularization and cellular repopulation occur.<sup>31</sup> Consequently, the graft may only act as a scaffold that provides a structure in which new tissue can grow. Tissue engineering has started to produce scaffolds for clinical use. The currently available matrices are Menaflex, formerly Collagen Meniscus Implant or CMI (ReGen Biologics, Franklin Lakes, NJ) and the recently introduced Actifit (Orteq Bioengineering, Groningen, Holland). Menaflex was the first to be developed and is a collagen matrix obtained from bovine Achilles tendon, whereas Actifit is a polyurethane implant. Nevertheless, these 2 meniscal substitutes are not suitable for total meniscal replacement. They require a meniscal rim and horn remnants for the implant to be properly fixed. Therefore, they are designed for partial meniscus replacement. Total meniscus substitution seems to be the next step for tissue engineering in this particular area. An experimental work that has shown promising results, has recently investigated the potential of a biologic scaffold seeded with chondrocytes for total meniscal substitution.<sup>48</sup>

Next generation tissue engineering for meniscal regeneration will probably combine improved scaffolding technology

with cell cultures and gene therapy. Eventually, tissue engineered products will 1 day compete against or even completely replace AMT.

### REFERENCES

- King D. The function of semilunar cartilages. *J Bone Joint Surg Am.* 1936;18:1069.
- Fairbank TJ. Knee joint changes after meniscectomy. *J Bone Joint Surg Br.* 1948;30:664–670.
- Jackson JP. Degenerative changes in the knee after meniscectomy. *Br Med J.* 1968;2:525–527.
- Tapper EM, Hoover NW. Late results after meniscectomy. *J Bone Joint Surg Am.* 1969;51:517–526.
- Lanzer WL, Komenda G. Changes in articular cartilage after meniscectomy. *Clin Orthop.* 1990;252:41–48.
- Krause WR, Pope MH, Johnson RJ, et al. Mechanical changes in the knee after meniscectomy. *J Bone Joint Surg Am.* 1976;58:599–604.
- Kurosawa H, Fukubayashi T, Nakajima H. Load-bearing mode of the knee joint. *Clin Orthop.* 1980;149:283–290.
- Seedhom BB, Hargreaves DJ. Transmission of load in the knee joint with especial reference to the role of menisci, part II: experimental results, discussions, and conclusions. *Eng Med Biol.* 1979;8:220–228.
- Milachowski K, Weismeier K, Wirth C. Homologous meniscus transplantation: experimental and clinical results. *Int Orthop.* 1989;13:1–11.
- Zukor DJ, Cameron JC, Brooks PJ, et al. The fate of human meniscal allografts. In: Ewing JW, ed. *Articular Cartilage and Knee Joint Function: Basic Science and Arthroscopy.* New York: Raven Press; 1990:147.
- Locht RC, Gross AE, Langer F. Late osteochondral resurfacing for tibial plateau fractures. *J Bone Joint Surg Am.* 1984;66:328–335.
- Wirth CJ, Peters G, Milachowski KA, et al. Long-term results of meniscal allograft transplantation. *Am J Sports Med.* 2002;30:174–181.
- Verdonk PCM, Verstraete KL, Almqvist KF, et al. Meniscal allograft transplantation: long-term clinical results with radiological and magnetic resonance imaging correlations. *Knee Surg Sports Traumatol Arthrosc.* 2006;14:694–706.
- Cameron JC, Saha S. Meniscal allograft transplantation for unicompartmental arthritis of the knee. *Clin Orthop.* 1997;337:164–171.
- Stone KR, Walgenbach AW, Turek TJ, et al. Meniscus allograft survival in patients with moderate to severe unicompartmental arthritis: a 2- to 7-year follow-up. *Arthroscopy.* 2006;22:469–478.
- Pollard ME, Kang Q, Berg EE. Radiographic sizing for meniscal transplantation. *Arthroscopy.* 1995;11:684–687.
- Gelber PE, Gonzalez G, Lloreta JL, et al. Freezing causes changes in the meniscus collagen net: a new ultrastructural meniscus disarray scale. *Knee Surg Sports Traumatol Arthrosc.* 2008;16:353–359.
- Gelber PE, Gonzalez G, Torres R, et al. Cryopreservation does not alter the ultrastructure of the meniscus. *Knee Surg Sports Traumatol Arthrosc.* 2009;17:639–644.
- Verdonk PCM, Demurie A, Almqvist KF, et al. Transplantation of viable meniscal allograft. *J Bone Joint Surg Am.* 2005;87:715–724.
- Yahia L, Drouin G, Zukor D. The irradiation effect on the initial mechanical properties of meniscal grafts. *Biomed Mater Eng.* 1993;3:211–221.
- Garret J, Stevenson R. Meniscal transplantation in the human knee: a preliminary report. *Arthroscopy.* 1991;7:57–62.

22. Alhalki MM, Howell SM, Hull ML. How three methods for fixing a medial meniscal autograft affect tibial contact mechanics. *Am J Sport Med.* 1999;27:320–328.
23. Sekaran SV, Hull ML, Howell SM. Nonanatomic location of the posterior horn of a medial meniscal autograft implanted in a cadaveric knee adversely affects the pressure distribution on the tibial plateau. *Am J Sports Med.* 2002;30:74–82.
24. Iñigo-Pavlovich R. Radiofrequency and meniscus. From excision to repair. *Sports Med Arthrosc Rev.* 2005;13:193–197.
25. Kohn D, Moreno B. Meniscus insertion anatomy as a basis for meniscus replacement: a morphological cadaveric study. *Arthroscopy.* 1995;11:96–103.
26. Berlet GC, Fowler PJ. The anterior horn of the medial meniscus: an anatomic study of its insertion. *Am J Sports Med.* 1998;26:540–543.
27. Farr J, Meneghini Rm, Cole BJ. Allograft interference screw fixation in meniscus transplantation. *Arthroscopy.* 2004;20:322–327.
28. DeBoer HH, Koudstaal J. Failed meniscal transplantation: a report of three cases. *Clin Orthop.* 1994;306:155–162.
29. Rijk PC. Meniscal allograft transplantation. Part I: background, results, graft selection and preservation, and surgical considerations. *Arthroscopy.* 2004;7:728–743.
30. Matava MJ. Meniscal allograft transplantation: a systematic review. *Clin Orthop.* 2007;455:142–157.
31. Lubowitz JH, Verdonk PCM, Reid JB, et al. Meniscus allograft transplantation: a current concepts review. *Knee Surg Sports Traumatol Arthrosc.* 2007;15:476–492.
32. Stollsteimer GT, Shelton WR, Dukes A, et al. Meniscal allograft transplantation: a 1- to 5-year follow-up of 22 patients. *Arthroscopy.* 2000;16:343–347.
33. van Arkel ERA, De Boer HH. Survival analysis of human meniscal transplantations. *J Bone Joint Surg Br.* 2002;84:227–231.
34. Graf KW, Sekiya JK, Wojtys EM. Long-term results after combined medial meniscal allograft transplantation and anterior cruciate ligament reconstruction: minimum 8.5-year follow-up study. *Arthroscopy.* 2004;20:129–140.
35. Yoldas EA, Sekiya JK, Irrgang JJ, et al. Arthroscopically assisted meniscal allograft transplantation with and without combined anterior cruciate ligament reconstruction. *Knee Surg Sports Traumatol Arthrosc.* 2003;11:173–182.
36. Rath E, Richmond JC, Yassir W, et al. Meniscal allograft transplantation. Two- to eight-year results. *Am J Sports Med.* 2001;29:410–414.
37. Rodeo SA, Seneviratne A, Suzuki K, et al. Histological analysis of human meniscal allografts, a preliminary report. *J Bone Joint Surg Am.* 2000;8:1071–1082.
38. Khoury MA, Goldberg VM, Stevenson S. Demonstration of HLA and ABH antigens in fresh and frozen human menisci by immunohistochemistry. *J Orthop Res.* 1994;12:751–757.
39. Wada Y. Meniscal transplantation using fresh and cryopreserved allografts. An experimental study in the genetically defined rat. *J Jpn Orthop Assoc.* 1993;67:677–683.
40. Hamlet W, Liu SH, Yang R. Destruction of a cryopreserved meniscal allograft: a case for acute rejection. *Arthroscopy.* 1997;13:517–521.
41. Puig L, Monllau JC, Corrales M, et al. Factors affecting meniscal extrusion: correlation with MRI, clinical, and arthroscopic findings. *Knee Surg Sports Traumatol Arthrosc.* 2006;14:394–398.
42. Lee DH, Kim TH, Lee SH, et al. Evaluation of meniscus allograft transplantation with serial magnetic resonance imaging during the first postoperative year: focus on graft extrusion. *Arthroscopy.* 2008;24:1115–1121.
43. Khetia EA, McKeon BP. Meniscal allografts: biomechanics and techniques. *Sport Med Arthrosc Rev.* 2007;15:114–120.
44. Jackson DW, McDevitt CA, Simon TM, et al. Meniscal transplantation using fresh and cryopreserved allograft: an experimental study in goats. *Am J Sports Med.* 1992;20:644–656.
45. Rijk PC, Van Noorden CFJ. Structural analysis of meniscal allograft after immediate and delayed transplantation in rabbits. *Arthroscopy.* 2002;18:995–1001.
46. Fritz JM, Irrgang JJ, Harner CD. Rehabilitation following allograft meniscal transplantation: a review of the literature and case study. *J Orthop Sports Phys Ther.* 1996;24:98–106.
47. Thompson WO, Thaete FL, Fu FH, et al. Tibial meniscal dynamics using three-dimensional reconstruction of magnetic resonance images. *Am J Sports Med.* 1991;19:210–216.
48. Kon E, Chiari C, Marcacci M, et al. Tissue engineering for total meniscal substitution: animal study in sheep model. *Tissue Eng Part A.* 2008;14:1067–1080.