

Myxoid Tumor Associated to Migration of a Suspensory Fixation Device of a Reconstructed Anterior Cruciate Ligament: A Case Report

Pablo Eduardo Gelber, MD, PhD^{1,2} Juan Ignacio Erquicia, MD² Xavier Pelfort, MD² Marc Tey, MD²
Juan Carlos Monllau, MD, PhD^{1,2}

¹ Department of Orthopaedic Surgery, Hospital de Sant Pau, Universitat Autònoma de Barcelona, Barcelona, Spain
² ICATME-Institut Universitari Dexeus, Universitat Autònoma de Barcelona, Barcelona, Spain

Address for correspondence Pablo Eduardo Gelber, MD, PhD, Department of Orthopedic Surgery, Hospital de Sant Pau, Universitat Autònoma de Barcelona, C/Sant Antoni Maria Claret, 167-08025 Barcelona, Spain (e-mail: pablogelber@gmail.com).

J Knee Surg 2013;26(Suppl 1):S50–S52.

Abstract

Keywords

- ▶ anterior cruciate ligament failure
- ▶ anterior cruciate ligament fixation
- ▶ XoButton
- ▶ graft fixation
- ▶ anterior cruciate ligament complication

A 16-year-old male who had undergone 6 months before an anterior cruciate ligament (ACL) reconstruction with an autologous hamstring graft fixed with a suspensory fixation device (XoButton device; ConMed Linvatec, Largo, FL), complained of a slightly painful mass in the distal posterolateral aspect of the thigh. The knee was otherwise stable. A 79 × 60 × 17 mm multilobulated tumor surrounding the implant device was observed in magnetic resonance images. The revision arthroscopy showed an intact ACL graft. The tumor was excised through a longitudinal posterolateral approach. It had a myxoid appearance. The undamaged implant was also removed. Two months after surgery, the patient was already asymptomatic. Although most fixation device problems occur in the perioperative period due to an inadequate technique which may lead to graft instability, this case reminds clinicians of the possibility of later developing clinically relevant complications with suspensory fixation devices.

Anterior cruciate ligament (ACL) reconstructions are among the most common sports medicine procedures performed each year. Different fixation devices have been developed to fix the graft at the femoral side. They are meant to provide initial stability to the graft while it is healing within the host bone tunnel. The so-called extracortical or suspensory fixation devices (SFD) fix the graft by flipping and hooking itself on the cortical bone surface. They have been shown to provide strong and secure fixation. They have adequate maximum pullout strength and show little graft-implant elongation while allowing for minimum micromotion due to their favorable loop material characteristics.^{1,2} Most of their potential complications are caused by improper technique that may compromise graft stability.^{3–6}

In this report, we describe a rare complication, which did not compromise knee stability, in which this kind of fixation

device has migrated proximally within a tumor, a few months after the procedure.

Case Report

Six months after having undergone ACL reconstruction with autologous hamstring graft surgery, a 16-year-old male presented himself at the orthopedic clinic complaining of tenderness in a mass in the distal posterolateral aspect of the thigh. In the index surgery, femoral fixation of the graft had been performed with a 15 mm XoButton (ConMed Linvatec, Largo, FL) suspensory fixation device. The femoral tunnel had been drilled anatomically through the anteromedial portal at 130 degrees of knee flexion. The mass had grown up in a 2-week period after a 72-hour motorcycle ride. He did not fall or twist, or bang his knee at any time. On physical

received
January 25, 2011
accepted
October 5, 2011
published online
May 3, 2012

Copyright © 2013 by Thieme Medical Publishers, Inc., 333 Seventh Avenue, New York, NY 10001, USA.
Tel: +1(212) 584-4662.

DOI <http://dx.doi.org/10.1055/s-0031-1299649>.
ISSN 1538-8506.

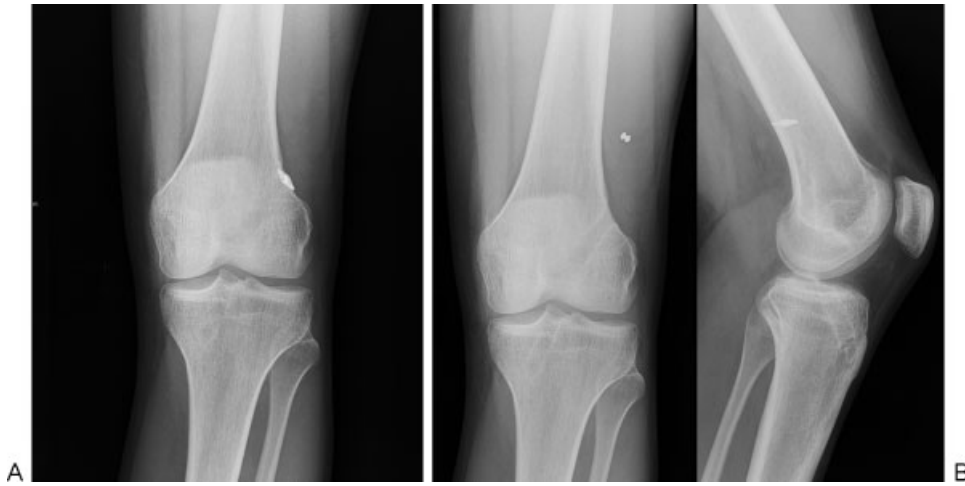

Fig. 1 Standard anteroposterior and lateral knee radiographs of the involved knee. (A) Immediate postoperative radiographs showed proper placement of the XoButton as well as the femoral and tibial tunnels. (B) Six months after the operation, the implant was seen 39 mm more proximally than in (A).

examination no instability was observed. Radiographic examination revealed that the implant had migrated 39 mm proximally in comparison to the immediate postoperative radiograph (►Fig. 1A, B). Magnetic resonance evaluation showed a 79 × 60 × 17 mm multilobulated tumor extending from the eroded exit of the femoral tunnel. The implant device was observed in its posteriormost area (►Fig. 2). The ACL graft was seen correctly positioned and it appeared to be in good condition. No alteration of the erythrocyte sedimentation rate (ESR) and C-reactive protein (CRP) level were observed.

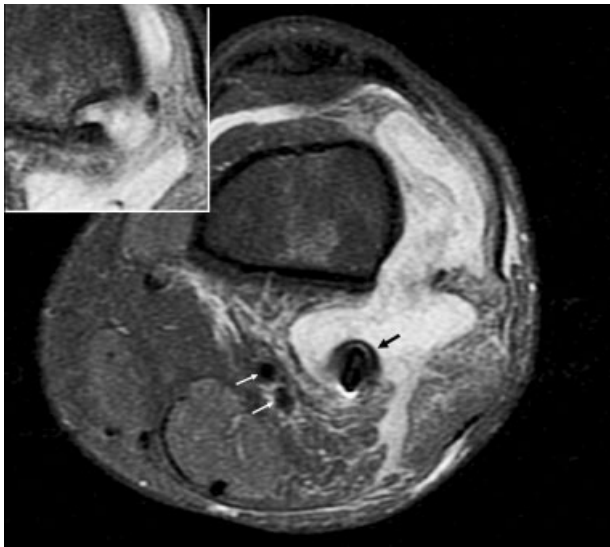


Fig. 2 MRI at 6 months after the ACL reconstruction showed a 79 × 60 × 17 mm multilobulated tumor. The implant device (black arrow) was observed in its posteriormost area. See its close proximity to the popliteal vessels (white arrows). The tumor looked as if it had originated from the eroded exit of the femoral tunnel (see upper left corner). ACL, anterior cruciate ligament; MRI, magnetic resonance imaging.

Subsequently, the patient underwent revision arthroscopy and excision of the tumor. The aforementioned arthroscopic revision showed an intact, integrated and stable ACL graft. The tumor was approached through a longitudinal posterolateral incision between the lateral septum of the tight and the biceps femoris muscle. A considerable amount of a myxoid matter was observed and subsequently excised. The implant was also removed. Surprisingly its loop was intact (►Fig. 3). Inspection of the exit of the femoral tunnel was unremarkable and no articular communication through it was observed. While microbiological culture analysis was negative, the pathoanatomic analysis reported on the presence of synovial tissue fragments and granulation tissue with intense lymphoplasmocitary inflammatory infiltrate associated with polymorphonuclears neutrophils.

Two months after surgery, the patient was already asymptomatic and the knee remained stable.

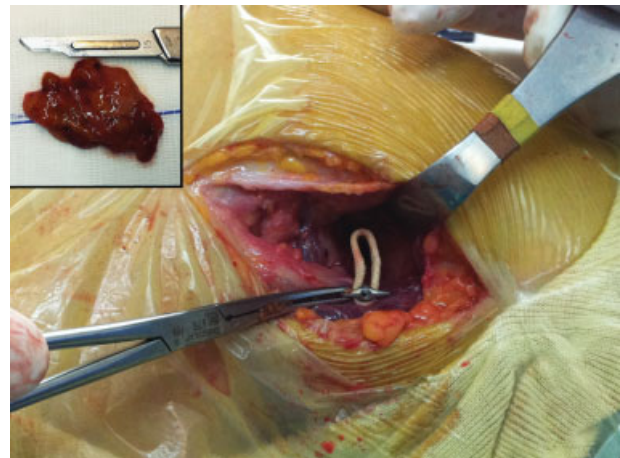


Fig. 3 Intraoperative view. The myxoid tumor (see upper left corner) was approached through a posterolateral incision. The 15 mm Xo-Button was found with its loop intact and it was subsequently removed from the posterior region of the mass.

Discussion

Suspensory fixation devices are one of the most commonly used soft tissue fixation systems in ACL reconstruction. They have been shown to be secure and strong enough because of their adequate maximum pull-out strength and tend to little graft-implant elongation.^{1,2} The contribution of the fixation systems to the stability of the graft decreases from time 0 and one can consider that it plays, at most, a secondary role in providing stability after 3 months of surgery.²

Potential complications with the suspensory fixation devices are femoral tunnel widening,^{1,2} femoral cortex necrosis and loosening due to jamming into the tunnel or falling into the joint,³ and soft tissue interpositioning.⁷ Breakage of the drill bit⁴ and drooping of a SFD into the knee joint^{5,8} have also been described. The later has been reported twice in the literature and the authors have suggested that the cause may have been loosening of the device due to synovial inflammation. In the present report, we have not found any logical reason for the proximal migration of the intact-loop XoButton. Immediate postoperative evaluation revealed that the implant was correctly deployed on the lateral cortex. Thus, such a proximal migration might have occurred as a result of the pushing effect of the forming myxoid tumor in a later period.

Synovial cyst formation following bioabsorbable screw fixation has been reported, as a consequence of direct communication with the knee joint because of failed osteointegration of the graft.⁷ However, the formation of a myxoid tumor, as observed in our case, does not suggest this type of causal effect either. The pathoanatomic examination of the mass also ruled out the possibility of a foreign body reaction (macrophages and giant cells surrounding the foreign body⁹). Although the histology shown a lymphoplasmocitary infiltrate associated with polymorphonuclears neutrophils, the fact that microbiology was negative, the normal levels of the ESR and CRP, the stability of the graft, and the favorable outcome after simply excision of the tumor are all arguments

against the possibility of an infection. Finally, most of the published complications relative to SFD have been reported with the use of the EndoButton system (Smith & Nephew, Andover, MA).^{3-6,8} To date and to our knowledge, this is the first report on a complication with the XoButton system.

Although most fixation device problems are caused by improper technique that may lead to graft stability compromise,^{3,4,6} this case reminds clinicians of later developing clinically relevant complications, other than those resulting in knee instability, with the suspensory fixation device when the graft is already integrated.

References

- 1 Conner CS, Perez BA, Morris RP, Buckner JW, Buford WL Jr, Ivey FM. Three femoral fixation devices for anterior cruciate ligament reconstruction: comparison of fixation on the lateral cortex versus the anterior cortex. *Arthroscopy* 2010;26(6):796-807
- 2 Kamelger FS, Onder U, Schmoelz W, Tecklenburg K, Arora R, Fink C. Suspensory fixation of grafts in anterior cruciate ligament reconstruction: a biomechanical comparison of 3 implants. *Arthroscopy* 2009;25(7):767-776
- 3 Karaoglu S, Halici M, Baktir A. An unidentified pitfall of Endobutton use: case report. *Knee Surg Sports Traumatol Arthrosc* 2002; 10(4):247-249
- 4 Miller MD. EndoButton drill bit failure. *Arthroscopy* 2002;18 (3):322-324
- 5 Muneta T, Yagishita K, Kurihara Y, Sekiya I. Intra-articular detachment of the Endobutton more than 18 months after anterior cruciate ligament reconstruction. *Arthroscopy* 1999;15(7):775-778
- 6 Simonian PT, Behr CT, Stechschulte DJ Jr, Wickiewicz TL, Warren RF. Potential pitfall of the EndoButton. *Arthroscopy* 1998;14(1): 66-69
- 7 Ahn JH, Lee YS, Chang MJ. Post-tibial cyst formation over 2 years after posterior cruciate ligament reconstruction. *Knee Surg Sports Traumatol Arthrosc* 2008;16(11):996-998
- 8 Yanmiş I, Tunay S, Oğuz E, Yildiz C, Ozkan H, Kirdemir V. Dropping of an EndoButton into the knee joint 2 years after anterior cruciate ligament repair using proximal fixation methods. *Arthroscopy* 2004;20(6):641-643
- 9 Anderson JM, Rodriguez A, Chang DT. Foreign body reaction to biomaterials. *Semin Immunol* 2008;20(2):86-100